



2017

# Case Report: An Undiagnosed Bladder Diverticulum Resulting in Foley Catheter Perforation During Cesarean Section

A. Allison Roy, Nadim Bou Zgheib, and Joseph Assaley

DOI: <http://dx.doi.org/10.18590/mjm.2017.vol3.iss3.4>

Follow this and additional works at: <http://mds.marshall.edu/mjm>

 Part of the [Obstetrics and Gynecology Commons](#)

## Recommended Citation

Roy, A. Allison; Bou Zgheib, Nadim; and Assaley, Joseph (2017) "Case Report: An Undiagnosed Bladder Diverticulum Resulting in Foley Catheter Perforation During Cesarean Section," *Marshall Journal of Medicine*: Vol. 3: Iss. 3, Article 4.

DOI: <http://dx.doi.org/10.18590/mjm.2017.vol3.iss3.4>

Available at: <http://mds.marshall.edu/mjm/vol3/iss3/4>

This Case Report is brought to you for free and open access by Marshall Digital Scholar. It has been accepted for inclusion in Marshall Journal of Medicine by an authorized editor of Marshall Digital Scholar. For more information, please contact [zhangj@marshall.edu](mailto:zhangj@marshall.edu), [martj@marshall.edu](mailto:martj@marshall.edu).

---

## References with DOI

1. Pierretti R. Congenital bladder diverticula in children. *Journal of Pediatric Surgery*. 1999;3(34):468-473. [https://doi.org/10.1016/s0022-3468\(99\)90501-8](https://doi.org/10.1016/s0022-3468(99)90501-8)
2. Shakeri S, et al. The incidence of diverticula of urinary bladder in patients with benign prostatic hypertrophy and the comparison between cystoscopy and cystography in detecting bladder diverticula. *Iranian Red Crescent Medical Journal*. 2007;9(1):36-41.
3. Garat J, et al. Primary congenital bladder diverticula in children. *Urology*. 2007;5(70):984-988. <https://doi.org/10.1016/j.urology.2007.06.1108>
4. Blaivas J, Chughtai B, Tsui JF, et al. Management of bladder diverticula. *Current Bladder Dysfunction Report*. 2011;6(198). <https://doi.org/10.1007/s11884-011-0108-5>
5. Eyraud R, Laydner H, Autorino R, et al. Robot assisted laparoscopic bladder diverticulectomy. *Current Urology Report*. 2013;14(46). <https://doi.org/10.1007/s11934-012-0290-9>
6. Johnsen N et al. Evaluating the role of operative repair of extraperitoneal bladder rupture following blunt pelvic trauma. *The Journal of Urology*. 2016;195(3):661-665. <https://doi.org/10.1016/j.juro.2015.08.081>

## **Case report: An undiagnosed bladder diverticulum resulting in Foley catheter perforation during cesarean delivery**

A. Allison Roy, MD<sup>1</sup>, Nadim Bou Zgheib, MD, FACOG<sup>1</sup>, Joseph Assaley, MD, FACOG<sup>2</sup>

### **Author Affiliations:**

1. Marshall University Joan C. Edwards School of Medicine, Huntington, West Virginia
2. Cabell Huntington Hospital, Huntington, West Virginia

The authors have no financial disclosures to declare and no conflicts of interest to report.

### **Corresponding Author:**

A. Allison Roy, MD  
Marshall University Joan C. Edwards School of Medicine  
Huntington, West Virginia  
Email: hogsett12@marshall.edu

## Abstract

A bladder diverticulum is diagnosed when herniated bladder mucosa forms an outpouching from the bladder. Bladder diverticula are uncommon and are significantly more common in males. The following case presents a patient with an undiagnosed bladder diverticulum which was incidentally perforated during Foley catheter placement for a repeat cesarean section. The diagnosis can be difficult in those who are asymptomatic and lack risk factors, such as the following patient.

## Keywords

bladder diverticulum, cesarean

## Introduction

A bladder diverticulum is an outpouching of herniated bladder mucosa that can be congenital or acquired.<sup>1</sup> Acquired diverticula are more common and the most common cause is chronic bladder outlet obstruction.<sup>2</sup> Obstruction can be caused by bladder neck stenosis, urethral stricture, neurogenic bladder, and benign prostatic hyperplasia (BPH) in males.<sup>2</sup> Bladder and pelvic surgery and some congenital syndromes such as Ehlers-Danlos syndrome are less common risk factors.<sup>1,3</sup> Males are nine times more likely to be diagnosed with a bladder diverticulum than females.<sup>2</sup>

Complications associated with bladder diverticula include recurrent urinary tract infection (UTI), cystolithiasis, reflux, and a 2-7% risk of bladder transitional cell carcinoma.<sup>2-4</sup> The diagnosis can be difficult to make since some bladder diverticula can also be asymptomatic.<sup>1,3</sup> We present a patient with undiagnosed bladder diverticulum which was incidentally perforated during Foley catheter placement for repeat cesarean delivery.

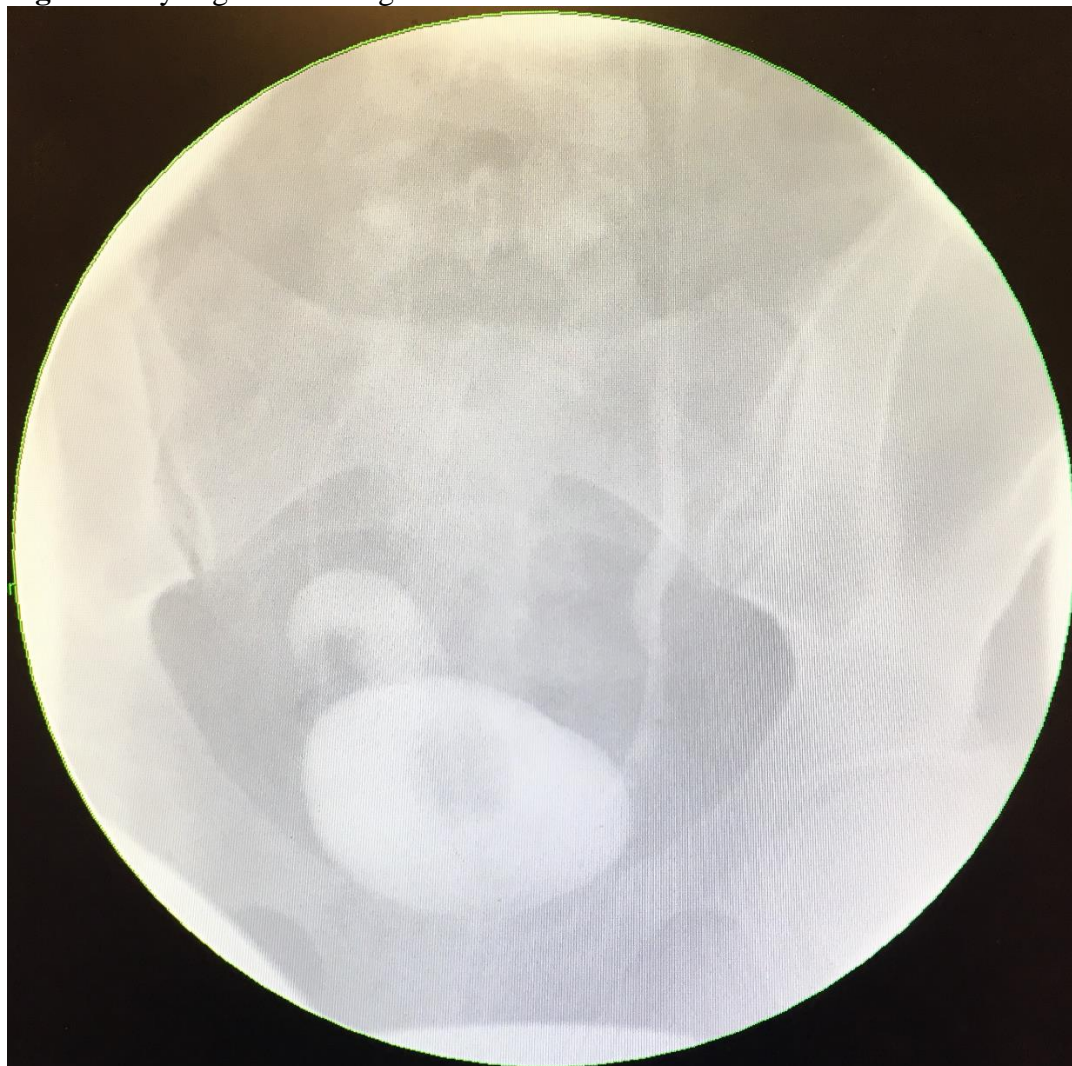## Case description

A thirty-nine-year old G3P2002 female at 38.3 weeks gestation was admitted for repeat cesarean delivery for gestational hypertension. Her pregnancy was otherwise only complicated by advanced maternal age. Her cesarean was unremarkable until closure of the uterus was being completed. Just as the uterus was being returned to its position inside the pelvis, the patient's Foley catheter emerged into the operative field. The Foley catheter had created an incidental perforation on the posterior portion of the patient's bladder. The cystotomy was localized several centimeters away from the immediate operative field. The patient's bladder was further dissected and cystorrhaphy was completed with the assistance of gynecologic oncology and urology. Interrupted chromic sutures were placed to close the bladder defect. Ureteral stents were also placed.

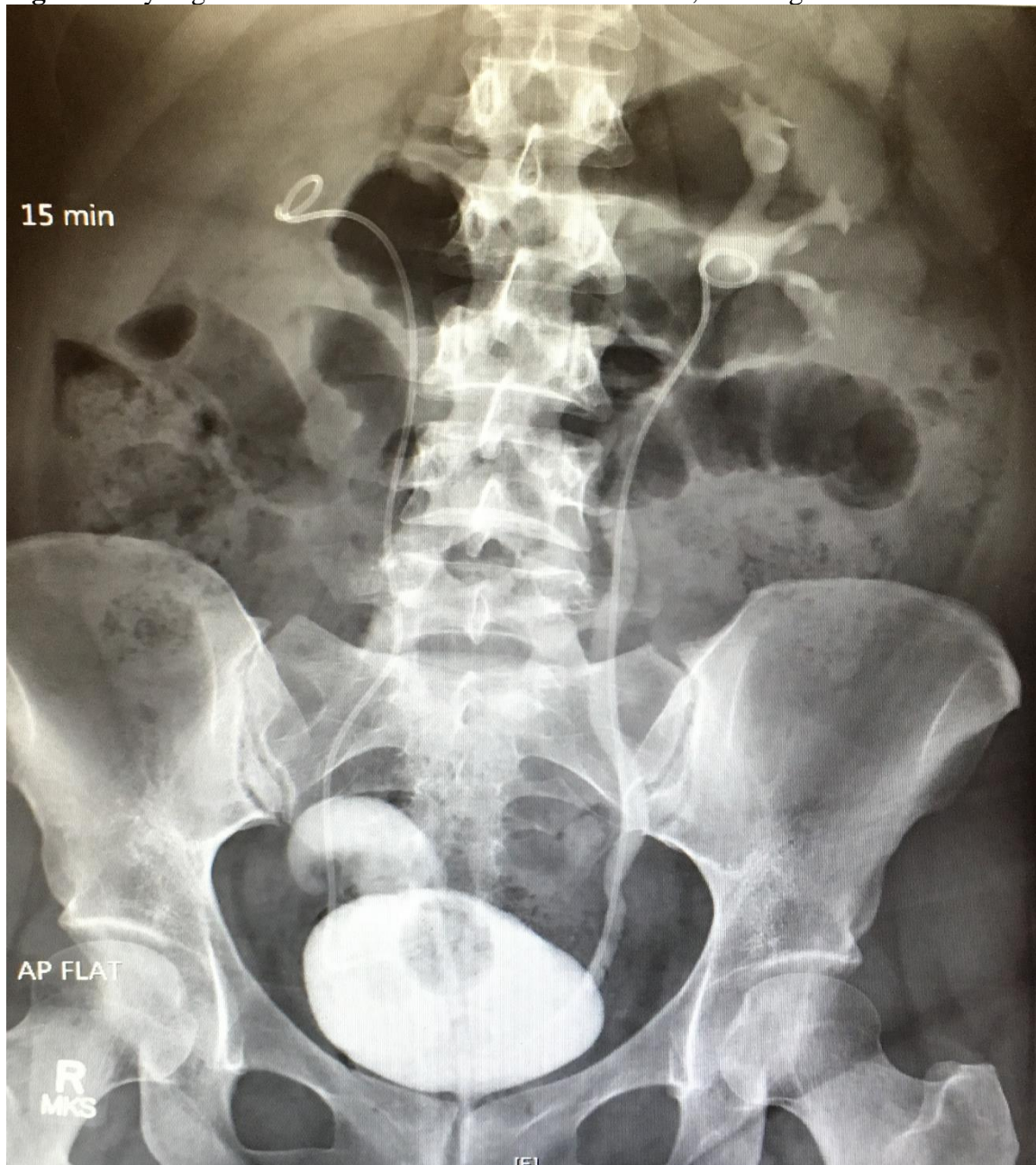
Cefazolin was continued for twenty-four hours postpartum and then cephalexin by mouth was given for UTI prophylaxis. Oxybutynin by mouth and belladonna and opium rectal suppositories were given to prevent bladder spasm. The patient was discharged on post-operative day 3 with her Foley catheter still in place. On post-operative day 12, a cystogram was performed and a

large 4x4.3x2.5 centimeter diverticulum was observed in the right anteroposterior portion of the bladder (**Figures 1-2**). No leak was observed. Cystoscopy was performed on post-operative day 18 and a diverticulum was noted at the dome of the bladder. The ureteral stents and Foley catheter were removed. The patient was instructed on timed double voiding. She was seen for 12 week follow up and was experiencing frequency but this gradually improved since Foley catheter removal.

**Figure 1.** Cystogram showing bladder diverticulum at bladder dome.



**Figure 2.** Cystogram 15 minutes after contrast introduction, showing bladder diverticulum.



## Discussion

The cause of the patient's diverticulum is unclear. She may have had a congenital bladder diverticulum that was asymptomatic and therefore never diagnosed until her Foley catheter created a cystostomy. Pelvic surgery is another possible cause of bladder diverticula.<sup>4,5</sup> Although

the patient had had two previous cesarean deliveries, bladder surgery is a more typical cause and the patient denied any previous bladder procedures.

Congenital syndromes associated with bladder diverticula include Ehlers-Danlos, Diamond-Blackfan, Menkes (kinky-hair), Eagle-Barrett (prune-belly), and Williams syndromes. This patient was ruled out for these congenital syndromes as they typically present early in life with abnormal physical attributes as well as lab derangements.<sup>1,3</sup>

Indications for bladder diverticula repair include insufficient voiding, chronic urinary tract infections, lithiasis or tumor within the diverticulum, and spontaneous diverticular rupture.<sup>4,5</sup> Bladder diverticulectomy is typically indicated and it is traditionally performed by open technique. Laparoscopic and robotic diverticulectomy are also an option based on the surgeon's comfort level with the operation.<sup>5</sup> If the diverticulum is not ruptured, a cystotomy is created at the bladder dome. Ureteral stents are placed to decrease the risk of ureteral injury. The mucosa of the bladder diverticulum is everted and removed. The defect is closed with 3-0 to 5-0 absorbable interrupted suture. A urinary catheter should remain in place for 5-10 days following the procedure. Diverticular excision is usually curative but if a cause of the bladder diverticulum has been pinpointed, the cause should be addressed. For example, if chronic outlet obstruction is the cause, the obstruction should be corrected.<sup>2,4,5</sup>

If a cystotomy at the bladder dome occurs, cystorrhaphy should be performed if the defect is larger than 1 centimeter. Defects less than 1 centimeter can be managed with a Foley catheter for 14 days. If cystorrhaphy is performed, two layers of interrupted absorbable 2-0 or 3-0 suture should be used for bladder repair. The bladder can be backfilled with sterile milk to ensure the repair is adequate. A Foley catheter should be left in place for 7-14 days. Prophylactic antibiotics are not required but can be given if deemed necessary.<sup>6</sup>

This patient's diverticulum was not excised at the time of perforation because the diverticulum could not be located at the time of repair of the cystotomy. This was likely due to the damage caused by the Foley perforation which was an irregularly shaped defect. Prophylactic antibiotics were used with this patient. Although this is not necessarily indicated, this was done due to the extent of the patient's cystorrhaphy.

This case illustrates that patients with undiagnosed diverticula are at risk of perforation with introduction of Foley catheters. This patient did not have strong risk factors for a diverticulum. Her bladder perforation could have been easily overlooked if the catheter had not moved very superiorly to the defect so that it was easily viewed in the operative field, alerting the surgeons to the cystotomy. Cystorrhaphy was performed and her Foley catheter was left in place to ensure appropriate healing and closure of her bladder. The patient's diverticulum can be repaired surgically at a future date, in particular if she experiences any symptoms. She will need close follow-up as she is at risk of complications including UTI, cystoliths, vesicoureteral reflux, and transitional cell bladder cancer.



## References

1. Pierretti R. Congenital bladder diverticula in children. *Journal of Pediatric Surgery*. 1999;3(34):468-473.
2. Shakeri S, et al. The incidence of diverticula of urinary bladder in patients with benign prostatic hypertrophy and the comparison between cystoscopy and cystography in detecting bladder diverticula. *Iranian Red Crescent Medical Journal*. 2007;9(1):36-41.
3. Garat J, et al. Primary congenital bladder diverticula in children. *Urology*. 2007;5(70):984-988.
4. Blaivas J, Chughtai B, Tsui JF, et al. Management of bladder diverticula. *Current Bladder Dysfunction Report*. 2011;6(198).
5. Eyraud R, Laydner H, Autorino R, et al. Robot assisted laparoscopic bladder diverticulectomy. *Current Urology Report*. 2013;14(46).
6. Johnsen N et al. Evaluating the role of operative repair of extraperitoneal bladder rupture following blunt pelvic trauma. *The Journal of Urology*. 2016;195(3):661-665.