



2018

Favorable Response of Advanced Superior Sulcus Non-Small Cell Lung Carcinoma to Gefitinib for 11 years complicated by Interval Development of Small Cell Carcinoma of the Lung.

Mark H. Cooper

DOI: <http://dx.doi.org/10.18590/mjm.2018.vol4.iss1.8>

Follow this and additional works at: <http://mds.marshall.edu/mjm>

 Part of the [Medicine and Health Sciences Commons](#)

Recommended Citation

Cooper, Mark H. (2018) "Favorable Response of Advanced Superior Sulcus Non-Small Cell Lung Carcinoma to Gefitinib for 11 years complicated by Interval Development of Small Cell Carcinoma of the Lung," *Marshall Journal of Medicine*: Vol. 4: Iss. 1, Article 8.

DOI: <http://dx.doi.org/10.18590/mjm.2018.vol4.iss1.8>

Available at: <http://mds.marshall.edu/mjm/vol4/iss1/8>

This Case Report is brought to you for free and open access by Marshall Digital Scholar. It has been accepted for inclusion in Marshall Journal of Medicine by an authorized editor of Marshall Digital Scholar. For more information, please contact zhangj@marshall.edu, martj@marshall.edu.

References with DOI

1. American Cancer Society Cancer facts and Figures. American Cancer Society, Atlanta, GA USA 2012.
2. Hirsch FR, Varella-Garcia M, Bunn PA, Di maria MV, Veve R, Bremmes RM et al. Epidermal growth factor receptor in non small cell lung cancer. *N Engl J Med.* 2002;346:92-98.
3. Paez JG, Janne PA, Lee JC, Tracy S Greulich H, Gabriel S et al. EGFR mutations in lung cancer: correlation with clinical response to gefitinib therapy. *Science.* 2004;304:1497-1500. <https://doi.org/10.1126/science.1099314>
4. Engelman JA, Janne PA. Mechanisms of acquired resistance to epidermal growth factor receptor tyrosine kinase inhibitors in non small cell lung cancer. *Clin Cancer Res.* 2008;14:2895-2899. <https://doi.org/10.1158/1078-0432.ccr-07-2248>
5. Fukuoka M et al. Biomarker analyses and final overall survival results from a phase III, randomized, open-label, first-line study of gefitinib versus carboplatin/paclitaxel in clinically selected patients with advanced non-small-cell lung cancer in Asia (IPASS). *J Clin Oncol.* 2011 Jul 20;29(21):2866- 74. <https://doi.org/10.1200/jco.2010.33.4235>
6. Douillard JY et al. First-line gefitinib in Caucasian EGFR mutation-positive NSCLC patients: a phase-IV, open-label, single-arm study. *Br J Cancer.* 2014 Jan 7;110:55-62. <https://doi.org/10.1038/bjc.2013.721>
7. Jiang S, Zhao J, Wang M et al. Small-cell lung cancer transformation in patients with pulmonary adenocarcinoma: a case report and review of literature. *Medicine.* 2016;95(6):e2752. <https://doi.org/10.1097/md.0000000000002752>
8. Sequist LV, Waltman BA, Santagata DD et al. Genotypic and histologic evolution of lung cancers acquiring resistance to EGFR inhibitors. *Science Translational Medicine.* 2011;3(75):75ra26. <https://doi.org/10.1126/scitranslmed.3002003>
9. Ware KE, Marshall ME, Heasley LR et al. Rapidly acquired resistance to EGFR tyrosine kinase inhibitors in NSCLC cell lines through de-repression of FGFR2 and FGFR3 expression. *B PLoS One.* 2010;5(11)e14117. <https://doi.org/10.1371/journal.pone.0014117>

Favorable response of advanced superior sulcus non-small cell lung carcinoma to gefitinib for 11 years complicated by interval development of small cell carcinoma of the lung

Mark H Cooper MD, PhD¹, Tracy Dobbs MD², Yehuda Z Lebowicz MD¹

Author Affiliations:

1. Marshall University, Huntington, West Virginia
2. Tennessee Cancer Specialists, Knoxville, TN

The authors have no financial disclosures to declare and no conflicts of interest to report.

Corresponding Author:

Mark Cooper MD, PhD
Marshall University
Huntington, West Virginia
Email: cooperma@marshall.edu

Abstract

Gefitinib is a medication that was originally developed as an epidermal growth factor receptor (EGFR) blocker. It has been used to treat non-small cell lung cancer with varying success. We describe a patient who presented with Pancoasts syndrome and was deemed surgically unresectable. He had limited success with chemotherapy and radiation but had an excellent response to the medication gefitinib. The patient was disease free for several years and after eleven years of follow up with CT scans, a PET CT showed an isolated area of FDG avidity which on biopsy was small cell carcinoma of the lung. The patient had been maintained continually on gefitinib (Iressa) for eleven years. Gefitinib treatment and continuing EGFR blockade invariably result in resistance to the medication and ultimate relapse. However in the present case, presumed sensitivity of the original tumor for a prolonged time period was noted, with development of either a new, small cell lung cancer, or histologic transformation. Similar cases have described this phenomenon of epithelial cancers treated with tyrosine kinase inhibitor blockade and development of small cell lung cancer; however, our case is unusual in that this transformation is observed over an eleven year time span.

Keywords

lung cancer, iressa, gefitinib, response

Introduction

Lung cancer is a leading cause of mortality worldwide. Overall survival has lagged behind the improved survival seen with breast cancer, prostate cancer and colorectal cancer patients.¹ A significant number of patients with lung cancer present at an advanced stage. CT screening aims to find patients with disease much earlier in their natural history.

The treatment of advanced non-small cell carcinoma of the lung with chemotherapy and/or radiation has been the mainstay of therapy. Newer medications with fewer side effects aim to improve survival, while preserving quality of life. Current therapies have focused on different inhibitors of the components of tumor biology. Monoclonal antibodies, such as Bevacizumab, can block angiogenesis by inhibiting vascular endothelial growth factor A. Epidermal growth factor receptor blockers, in the form of tyrosine kinase inhibitors, have been developed to block the EGFR ligand. EGFR can be activated by epidermal growth factor and TGF alpha. EGFR plays an important role in cell proliferation, and mutations that activate this pathway promote cell proliferation and survival. Examples of agents that block EGFR include erlotinib (Tarceva), gefitinib (Iressa), afatinib and oimertinib.² Erlotinib has been shown to be effective in the treatment of tumors with EGFR activity translating into improved survival.³ Unfortunately, most patients ultimately develop resistance.

The biology of resistance mechanisms of lung cancer to medical therapy is complex and is still poorly understood. The consequences of prolonged EGFR blockade are unknown,

but in most cases relapse of the original tumor occurs.⁴ We describe a case of a patient with advanced right sided superior sulcus (Pancoast tumor) of the lung who had a poor response to chemotherapy and radiation. The patient responded extremely well to gefitinib. After ten years of CT surveillance the patient developed an isolated area of biopsy proven small cell lung cancer in the bronchus intermedius and right middle lobe. The new site of FDG uptake was different when compared to the patient's initial tumor presentation site. He is currently receiving systemic chemotherapy and radiation treatment. Previous studies have reviewed the clinical characteristics of transformed small cell lung cancer and whether this represents a new subtype of small cell carcinoma.

Case report

A 55 year old Caucasian male with a prior smoking history presented twelve years ago with symptoms attributed to Pancoast syndrome. Symptoms included neuropathy due to locally advanced malignancy. Biopsy revealed an undifferentiated non-small cell lung carcinoma without typical squamous although with some glandular differentiation. Radiologically, the tumor was locally invasive into the surrounding mediastinal structures and the patient was deemed not a surgical candidate. He was initially treated with conventional chemotherapy and radiation but had a relatively poor response radiologically and clinically. He was then commenced on the medication gefitinib in April 2004 and was noted to have a sustained response to therapy. There was interval resolution of tumor mass as assessed by follow up CT scans. No genetic testing was available at that time, and his mutation status was unknown. The patient had ceased to smoke at the time of his original lung cancer diagnosis twelve years ago.

His dramatic radiologic and clinical response perhaps implied that he very likely had an EGFR activating mutation. He was maintained on gefitinib for eleven years in remission, and maintained an excellent performance status. Past medical history included myocardial infarction and a left nephrectomy. He had no occupational exposure. The patient had never used oxygen at home and was able to climb a flight of stairs with relative ease. Blood tests were normal.

As part of ongoing surveillance, a chest CT scan prompted a PET/CT scan which showed a new area of FDG avidity, situated near the right bronchus intermedius of approximately 12 x 17 mm in size (Figure 1). This was concerning for tumor recurrence. The new FDG avid area was in a different site as compared to the patient's original tumor site. There were no other areas of concern. Physical examination showed a thin Caucasian male with normal vital signs. He had no palpable lymphadenopathy, and clinical examination of the chest revealed no abnormality. Bronchoscopy was scheduled with the intent of obtaining a transbronchial needle aspiration biopsy. Partially occlusive endobronchial disease was found in and around the middle lobe bronchus and conventional biopsies were obtained. (Figure 2). Histopathology showed small cell carcinoma. The patient was commenced on conventional chemotherapy and radiation for small cell lung cancer. He continues to have good performance status.

Figure 1: Pet/CT scan from 2014 in a 55 year old Caucasian male with a history of Pancoasts syndrome and a complete response to Iressa. There is an FDG avid right hilar mass confirmed on bronchoscopic biopsy to be small cell carcinoma. The patient is receiving treatment with radiation and chemotherapy.

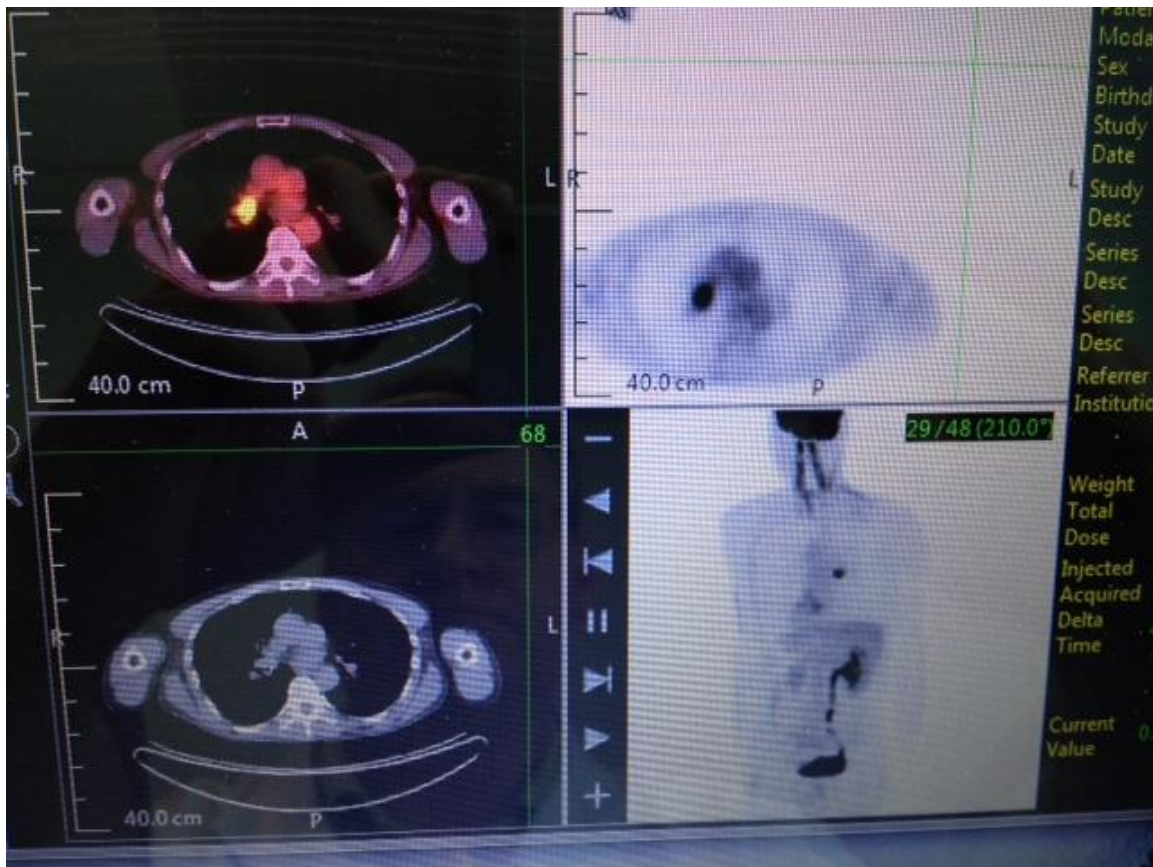
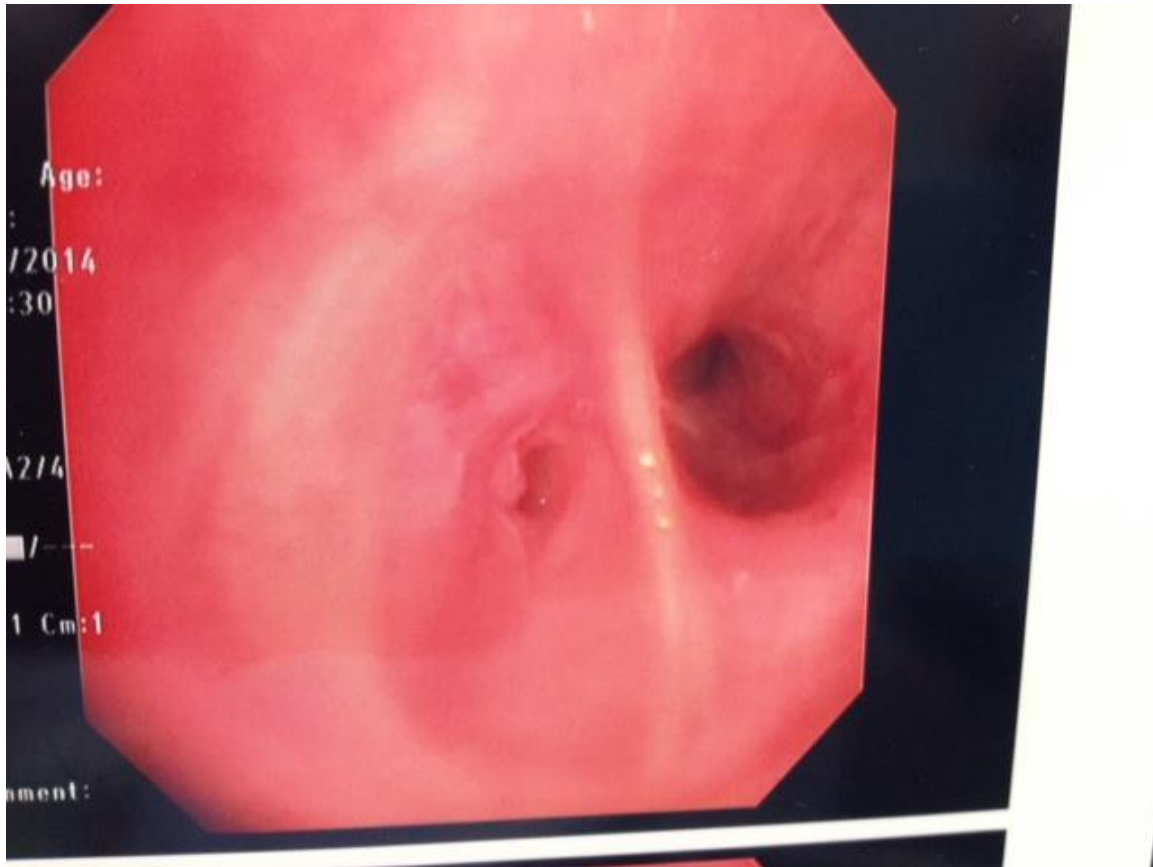


Figure 2: Bronchoscopic view of an endobronchial lesion encountered during the bronchoscopic procedure in a 55 year old Caucasian male with a history of Pancoasts syndrome that responded to Iressa. The Olympus bronchoscope finds endobronchial disease that is partially occlusive in the right middle lobe. Biopsies showed small cell lung cancer. The patient is undergoing treatment for localized small cell lung cancer.



Discussion

Gefitinib is an EGFR tyrosine kinase receptor blocker. It was the first generation of EGFR blockers used to treat patients with advanced non-small cell lung cancer who had failed chemotherapy.³ Although NSCLC is the most common type of lung cancer, EGFR gene mutations occur in about 10% of NSCLC tumors, as assessed by the National Cancer Institute. Gefitinib is intended for the treatment of patients whose tumors express the most common types of EGFR mutations in NSCLC tumors: exon 19 deletions or exon 21 L858R substitution gene mutations. The diagnostic test, known as the theascreen EGFR RGQ PCR Kit, identifies patients who have these very specific EGFR gene mutations. The US Food and Drug Administration announced in 2015 the approval of gefitinib for first-line treatment of patients with metastatic non-small cell lung cancer (NSCLC) whose tumors contain specific types of epidermal growth factor receptor (EGFR) gene mutations. The new approval represented a reversal of an earlier decision for the drug in the United States.

Gefitinib originally received accelerated approval in 2003 for the treatment of patients with advanced NSCLC after progression on platinum chemotherapy. However, the drug was withdrawn from the market after confirmatory trials failed to verify clinical benefit; at that time, it was not known that the drug effectiveness was limited to mutation-specific patients.⁵

The FDA approval of gefitinib was based on results from a multicenter, single-group clinical trial of 106 patients with metastatic NSCLC that was EGFR mutation–positive and previously untreated. After treatment with gefitinib (250 mg once daily), 50% of patients had an objective response. The response rates were similar in patients whether their tumors had EGFR exon 19 deletions or exon 21 L858R substitution mutations. These results are complimented by another clinical trial, in which 186 patients had metastatic, EGFR-positive NSCLC and received first-line treatment with gefitinib. The patients randomly assigned to receive gefitinib had better progression-free survival than patients receiving standard chemotherapy (such as four to six cycles of carboplatin/paclitaxel).⁶ Thus, the current approval is for a patient population, notably EGFR mutation–positive patients who were previously untreated, which is different than that of the 2003 approval.

In clinical trials, groups of patients with stages three and four lung cancer receiving gefitinib experienced a significantly longer period of progression-free survival (9.2 months) compared with patients who received platinum/Taxanes (6.3 months). Toxicity was tolerable for both groups and grade 3/4 adverse events were rare. The patient in the present report had a very favorable response to gefitinib when conventional chemotherapy had been relatively unsuccessful. The patient in the present report was not tested for genetic mutations and had a diagnosis of undifferentiated non-small cell carcinoma. State of the art treatment for advanced unresectable non-small cell lung cancer includes DNA testing to identify tumors that are EGFR positive. Treatment is usually initiated with newer EGFR blockers such as erlotinib. Response rates of patients with EGFR positive tumors treated with erlotinib are high. Patients with adenocarcinoma are more likely to exhibit the EGFR, although even these patients are in a minority group.

Side effects of gefitinib include nausea, emesis, reduced appetite, rash itching, acne and weakness. Gefitinib may cause serious adverse effects including interstitial lung disease, liver damage, gastrointestinal perforation, severe diarrhea, and ocular disorders. The most common adverse effects are diarrhea and skin reactions (including rash, acne, dry skin, and pruritus).

There is documented evidence of development of small cell lung cancer in patients treated with tyrosine kinase inhibitors.^{7,8} Our patient had been treated for more than ten years with gefitinib, which is a much longer time period than is documented in other studies for the development of small cell lung cancer that. Previous authors have suggested mechanisms that may account for the switch between non-small cell lung cancer of epithelial origin and small cell lung cancer.⁷ These authors' hypotheses include the possibility of de-differentiation of a well-defined epithelial cancer to a small cell lung cancer or a second possibility, such as the co-existence of two succinct progenitor types of cell from epithelial and neuroendocrine origins, these cells being present at the initial cancer presentation. Yet a third mechanism could be the existence of both types of

established tumor but with small cell lung cancer being present in very small amounts that can be missed through sampling error. Taken together, it is our view that there is a loss of epithelial cellular differentiation, by blockade with tyrosine kinase inhibitors. This may allow the cells to seek another pathway of differentiation to a different cell type. This leads to histologic transformation.

Studies in vitro have shown that chronically adapted non-small cell lung cancer cell lines have induction of fibroblast growth factor mRNA and protein.⁹ These in vitro studies suggest that other proteins that have adapted in cells as a result of chronic stimulation do occur, and may therefore become subsequent targets for the development of other novel medications to target treatment.

There is relatively new data regarding lung cancer screening. Current guidelines include recommendations for patients between ages 55 to 80 years old with a 30 pack year smoking history. There is a twenty percent improvement in survival in the CT scan screened patient cohort compared to those followed by chest X ray. The National Comprehensive Cancer Network (NCCN) guidelines also suggest continued follow up with CT scans for patients with lung cancer to monitor their responses to treatment. We support the idea of continued follow up, since our patient in this report has developed either another primary tumor albeit of a different histological type or histologic transformation of the original disease. In this present patient, development of new malignancy may be related to those risk factors that initiated the original tumor. The other possibilities include a loss of effectiveness of gefitinib and/or interference with cellular mechanisms that may protect the body against subsequent tumor initiation. For each interaction with a receptor, there is another effect on the cell that will trigger another series of molecular mechanisms that affects the cell in a different way. Lung cancer patients with metastatic disease should be followed every three to six months with a CT scan. Most patients treated with EGFR blockade therapy are treated between one to two years before they relapse. It is uncommon for patients to be maintained on EGFR blockade for eleven years.

References

1. American Cancer Society Cancer facts and Figures. American Cancer Society, Atlanta, GA USA 2012.
2. Hirsch FR, Varella-Garcia M, Bunn PA, Di maria MV, Veve R, Bremmes RM et al. Epidermal growth factor receptor in non small cell lung cancer. *N Engl J Med.* 2002;346:92-98.
3. Paez JG, Janne PA, Lee JC, Tracy S Greulich H, Gabriel S et al. EGFR mutations in lung cancer: correlation with clinical response to gefitinib therapy. *Science.* 2004;304:1497-1500.
4. Engelman JA, Janne PA. Mechanisms of acquired resistance to epidermal growth factor receptor tyrosine kinase inhibitors in non small cell lung cancer. *Clin Cancer Res.* 2008;14:2895-2899.
5. Fukuoka M et al. Biomarker analyses and final overall survival results from a phase III, randomized, open-label, first-line study of gefitinib versus carboplatin/paclitaxel in clinically selected patients with advanced non-small-cell lung cancer in Asia (IPASS). *J Clin Oncol.* 2011 Jul 20;29(21):2866-74. doi: 10.1200/JCO.2010.33.4235.
6. Douillard JY et al. First-line gefitinib in Caucasian EGFR mutation-positive NSCLC patients: a phase-IV, open-label, single-arm study. *Br J Cancer.* 2014 Jan 7;110:55-62. doi: 10.1038/bjc.2013.721
7. Jiang S, Zhao J, Wang M et al. Small-cell lung cancer transformation in patients with pulmonary adenocarcinoma: a case report and review of literature. *Medicine.* 2016;95(6):e2752.
8. Sequist LV, Waltman BA, Santagata DD et al. Genotypic and histologic evolution of lung cancers acquiring resistance to EGFR inhibitors. *Science Translational Medicine.* 2011;3(75):75ra26.
9. Ware KE, Marshall ME, Heasley LR et al. Rapidly acquired resistance to EGFR tyrosine kinase inhibitors in NSCLC cell lines through de-repression of FGFR2 and FGFR3 expression. *B PLoS One.* 2010;5(11)e14117.