

# Enterogenous cyst of the small bowel causing intussusception in an adult: Case report and review of literature

Nihar Shah<sup>1,2</sup>,  
Therese Lizardo-Escano<sup>1</sup>,  
Hamid Shaaban<sup>1</sup>,  
Gautamy Dhadham<sup>2</sup>,  
Arya Karki<sup>2</sup>, Robert Spira<sup>1</sup>

<sup>1</sup>Department of Internal Medicine, Saint Michael's Medical Center, Newark, <sup>2</sup>Department of Gastroenterology, Saint Joseph's Regional Medical Center, Paterson, NJ, USA

**Address for correspondence:**

Dr. Hamid Shaaban, Saint Michael's Medical Center, Newark, NJ, USA.  
E-mail: hamidshaaban@gmail.com

## Abstract

Small bowel intussusception is a rare congenital disease entity, mostly manifesting before the age of two with abdominal pain and acute intestinal obstruction. In adults, colon intussusception is a rare event causing approximately 1% of all acute intestinal obstructions and they can occur idiopathically in adults or due to an intraluminal tumor mass. We report a case of an enterogenous cyst causing intussusception and iron deficiency anemia in an adult treated by surgical excision and resection of the small bowel.

**Key words:** Enterogenous cyst, intussusception, small bowel

## INTRODUCTION

An enterogenous cyst is a rare finding usually detected during infancy or childhood.<sup>[1]</sup> Duplications in the midgut are the most common with the majority of cases reported in the distal small bowel.<sup>[2]</sup> Enterogenous cysts are separate entities from the GI tract and contain their own lumen. Hence, they expand and become symptomatic as their mucosa is functional and secretes fluid. Symptoms most commonly present in the 1<sup>st</sup> year of life and only a few cases have been described in the adult population. Clinical manifestations of enterogenous cysts include obstruction and less commonly, intussusception or gastrointestinal (GI) bleed.<sup>[2]</sup> The incidence of non-idiopathic or secondary intussusception is 5-6% with enterogenous cysts presenting as rare instances.<sup>[3]</sup> Lead point lesions are more commonly identified as diverticula and lymphomas. GI bleed is an additional complication and may originate from ulcerations, abrasions, or irritation to the mucosal layer within the duplication cyst, which subsequently results in gradual or brisk blood loss. Once identified, enterogenous cysts should be resected because complications can be fatal. Although initial symptoms may include nausea, emesis, or abdominal pain, symptoms may evolve to more serious conditions. Lesions can be detected by X-ray, ultrasound, or computed tomography (CT) scan. Small lesions may be missed on radiography. As such, follow-up with ultrasound or CT scan is recommended for further investigation.<sup>[4,5]</sup> We report a case of an enterogenous cyst

causing intussusception and iron deficiency anemia (IDA) in an adult treated by surgical excision and resection of the small bowel.

## CASE REPORT

The present case is about a 34-year-old male with no past medical history presented with diffuse intermittent abdominal pain for 3 months. He denied any change in bowel habits, recurrent vomiting, or palpable mass. He did note a 10 lb weight loss. On examination, he was clinically anemic with conjunctival pallor. Out-patient blood work-up showed hypochromic and microcytic anemia consistent with IDA. Fecal occult blood was positive. Out-patient esophagogastroduodenoscopy (EGD) and colonoscopy were done to further investigate the cause of IDA. EGD showed non-erosive gastritis. Colonoscopy was unremarkable. CT scan was ordered for further investigation, which showed distal small bowel intussusception [Figure 1]. Symptoms worsened so laparoscopic exploration was performed and a large mass with an area of intussusception was identified in the mid ileum. The muscularis propria between the bowel and cyst appeared continuous. The remainder of the small bowel had no noted abnormalities. A small incision was made and the affected portion of the bowel, including the cystic mass, was resected and an end to end anastomosis was performed. Pathological findings were consistent

with the diagnosis of an enterogenous cyst of the small bowel causing intussusception. Microscopically, the cyst was lined with small bowel epithelium [Figure 2]. Diffuse inflammation and ulcerations were noted in the lining [Figure 3]. Overall, these features were consistent with that of an enterogenous duplication cyst that was both the lead point for intussusception and a source of blood loss. The patient's post-operative course was uneventful as he recovered well with no complications. He was discharged home and he remained asymptomatic at 2 weeks follow-up. Blood parameters returned to normal following surgery.

## DISCUSSION

Although enterogenous cysts are rare, they are an important cause of intussusception and IDA. One of the earliest reviews of enterogenous cysts was published in 1956. Cysts were most commonly found in the midgut (50%), with the foregut (36%) and hindgut (12%) trailing and few cases (2%) were reported in extraintestinal spaces such as the retroperitoneum, spine and oropharynx.<sup>[6]</sup> Several theories exist regarding the origin of these cysts. The most widely accepted explanation for cyst formation is that duplication of the gut occurs due to pinching off of a diverticulum during embryological development.<sup>[6]</sup> Once formed, the enteric cyst becomes an integral part of the small bowel with continuous mesentery and separate mucosal-submucosal layers. As the lining of the cyst is completely functional, yet separate from the intestine, cysts can gradually expand because the mucosal surface secretes contents that promote its development. As such, symptoms predominate in the 1<sup>st</sup> year of life while the cyst is enlarging.

The majority of enterogenic cysts have been reported in infants. Adult cases have been documented, but are rare in comparison to children as symptoms most commonly present between the ages of 6 months to 2 years.<sup>[7]</sup> Symptoms include pain, emesis, palpable abdominal masses and bright red blood per rectum.<sup>[8]</sup> The most commonly reported symptom is small bowel obstruction likely secondary to growing cysts encroaching adjacent bowel lumen.<sup>[9]</sup> Rarely, enterogenous cysts may serve as lead points for intussusception. Ein described a review of 31 patients at the Hospital for Sick Children in Toronto. Of these 31 cases, only 2 intussusceptions were noted to have occurred secondary to duplication cysts.<sup>[8]</sup> A large Chinese study of 377 subjects showed no secondary cause of intussusception.<sup>[10]</sup> Furthermore, a European series of 145 cases noted a causative lesion in only 8 (5.6%) of cases, of which 1 was a duplication cyst.<sup>[11]</sup>

Only a few instances of small bowel duplication cysts have been described in adults. These cases were rarely associated with intussusception, but rather, IDA. Etiology of anemia varied from ulceration, perforation of mucosa, disruption of the common blood supply, or malignancy.<sup>[6]</sup> Zamir *et al.* in their study have reported

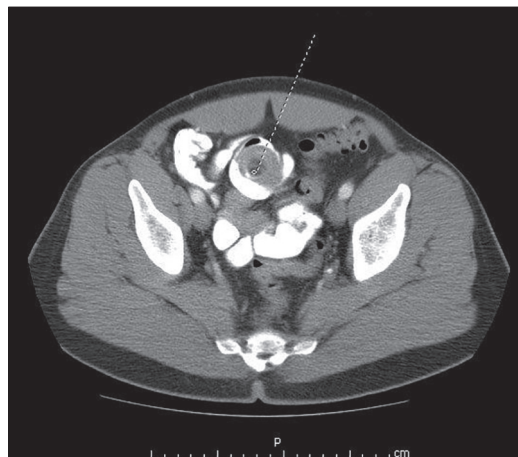


Figure 1: Computed tomography scan of abdomen

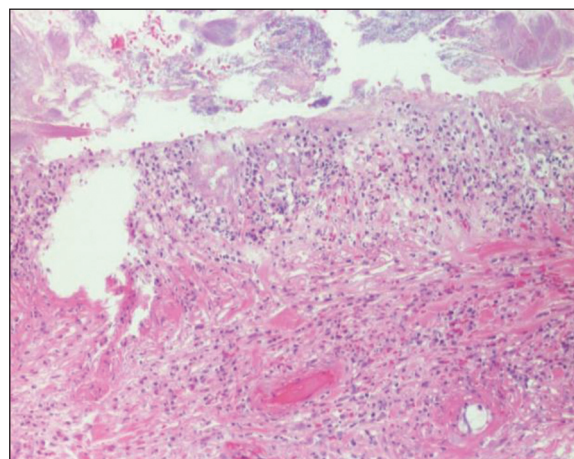


Figure 2: Pathology demonstrating small bowel inflammation

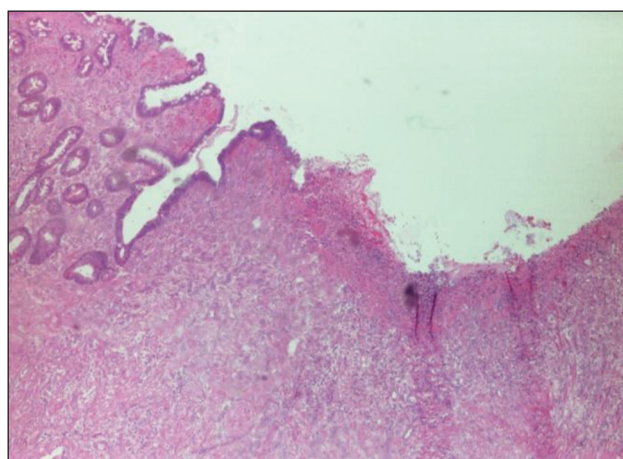


Figure 3: Pathology demonstrating ulceration of the small bowel

a case of an enterolith filled duodenal duplication cyst causing intussusception and hyperbilirubinemia in a 17-year-old boy.<sup>[1]</sup> Klingler *et al.* reviewed 3 adult cases of small intestinal enteroliths causing small bowel obstruction, but none of these cases led to intussusception.<sup>[12]</sup> Michael describes a review of world literature that confirms 25 duplication cysts in adults, but cysts were found in the rectum and did not lead to intussusception.<sup>[13]</sup> Instead, 3 of these cases presented with IDA secondary to adenocarcinoma of the rectal duplication cyst. Tamvakopoulos *et al.* reports a more recent case of IDA caused by a jejunal duplication cyst in a 48-year-old female.<sup>[6]</sup> Anemia was secondary to ulcerations as the cyst was lined with gastric mucosa.

It is important to identify patients who require surgical intervention for symptoms related to duplication cyst complications, such as intussusception and GI bleed, which may lead to death. Radiographs can identify the precise site of origin of duplication cysts.<sup>[14]</sup> If complete obstruction is not present, an upper GI series with small bowel follow through is appropriate for examination.<sup>[14]</sup> Ultrasonography is the most common imaging modality used for detection of intussusception.<sup>[7]</sup> A doughnut configuration may be seen on transverse view while a pseudokidney configuration may appear on longitudinal view.<sup>[3]</sup> The detection of excess fluid should lead to suspicion for a lead point lesion. CT scan is also helpful with defining culprit lesions. After lead points have been identified, resection of the affected intestine and the cyst is recommended to avoid complete obstruction and further complications.<sup>[4]</sup> Air or barium enema has been utilized to reduce intussusception in children without cystic lead points.<sup>[11]</sup>

## CONCLUSION

Enterogenous cysts are an uncommon cause of intussusception and IDA in adults. Although these cysts are rare, they are an important and potentially fatal cause of intestinal obstruction and GI bleed. Identification with X-ray, ultrasound, CT scan, or upper GI series with small bowel follow through serve as major diagnostic tools for evaluation. Treatment of choice is resection of the lead point with adjacent small intestine and end to end anastomoses.

## REFERENCES

- Zamir G, Gross E, Shmushkevich A, Bar-Ziv J, Durst AL, Jurim O. Duodenal duplication cyst manifested by duodeno-jejunal intussusception and hyperbilirubinemia. *J Pediatr Surg* 1999;34:1297-9.
- Arbell D, Lebenthal A, Blashar A, Shmushkevich A, Gross E. Duplication cyst of the duodenum as an unusual cause of massive gastrointestinal bleeding in an infant. *J Pediatr Surg* 2002;37:E8.
- Kenney IJ. Ultrasound in intussusception: A false cystic lead point. *Pediatr Radiol* 1990;20:348.
- Gordimer H, Bluestone L. Enterogenous cyst of the duodenum; a case report. *Ann Surg* 1950;132:1149-53.
- Adams TW. Obstructing enterogenous cyst of the duodenum treated by cystojejunostomy. *Ann Surg* 1956;144:902-6.
- Tamvakopoulos GS, Sams V, Preston P, Stebbings WS. Iron-deficiency anaemia caused by an enterolith-filled jejunal duplication cyst. *Ann R Coll Surg Engl* 2004;86:W49-51.
- Adamsbaum C, Sellier N, Helardot P. Ileocolic intussusception with enterogenous cyst: Ultrasonic diagnosis. *Pediatr Radiol* 1989;19:325.
- Ein SH. Leading points in childhood intussusception. *J Pediatr Surg* 1976;11:209-11.
- Ackerman NB. Duodenal duplication cysts: Diagnosis and operative management. *Surgery* 1974;76:330-3.
- Pracros JP, Tran-Minh VA, Morin de Finfe CH, Deffrenne-Pracros P, Louis D, Basset T. Acute intestinal intussusception in children. Contribution of ultrasonography (145 cases). *Ann Radiol (Paris)* 1987;30:525-30.
- Wang GD, Liu SJ. Enema reduction of intussusception by hydrostatic pressure under ultrasound guidance: A report of 377 cases. *J Pediatr Surg* 1988;23:814-8.
- Klingler PJ, Seelig MH, Floch NR, Branton SA, Metzger PP. Small-intestinal enteroliths — Unusual cause of small-intestinal obstruction: Report of three cases. *Dis Colon Rectum* 1999;42:676-9.
- Michael D, Cohen CR, Northover JM. Adenocarcinoma within a rectal duplication cyst: Case report and literature review. *Ann R Coll Surg Engl* 1999;81:205-6.
- Teele RL, Henschke CI, Tapper D. The radiographic and ultrasonographic evaluation of enteric duplication cysts. *Pediatr Radiol* 1980;10:9-14.

**How to cite this article:** Shah N, Lizardo-Escañó T, Shaaban H, Dhadham G, Karki A, Spira R. Enterogenous cyst of the small bowel causing intussusception in an adult: Case report and review of literature. *J Nat Sc Biol Med* 2015;6:208-10.

**Source of Support:** Nil. **Conflict of Interest:** None declared.

### Access this article online

Quick Response Code:



**Website:**  
www.jnsbm.org

**DOI:**  
10.4103/0976-9668.149124