



2016

Cardiomyopathy Secondary to Thyroid and Parathyroid Dysfunction: Case Report and Literature Review

Yousef H. Darrat, Todd W. Gress, Ellen A. Thompson, Paulette S. Wehner, and Mitch Charles

DOI: <http://dx.doi.org/10.18590/mjm.2016.vol2.iss1.3>

Follow this and additional works at: <http://mds.marshall.edu/mjm>

Recommended Citation

Darrat, Yousef H.; Gress, Todd W.; Thompson, Ellen A.; Wehner, Paulette S.; and Charles, Mitch (2016) "Cardiomyopathy Secondary to Thyroid and Parathyroid Dysfunction: Case Report and Literature Review," *Marshall Journal of Medicine*: Vol. 2: Iss. 1, Article 3.

DOI: <http://dx.doi.org/10.18590/mjm.2016.vol2.iss1.3>

Available at: <http://mds.marshall.edu/mjm/vol2/iss1/3>

This Case Report is brought to you for free and open access by Marshall Digital Scholar. It has been accepted for inclusion in Marshall Journal of Medicine by an authorized editor of Marshall Digital Scholar. For more information, please contact zhangj@marshall.edu, martj@marshall.edu.

References with DOI

1. Altunbaş H, Balci MK, Yazicioğlu G, Semiz E, Ozbilim G, Karayalçın U. Hypocalcemic cardiomyopathy due to untreated hypoparathyroidism. *Hormone Research* 2003; 59(4):201-4. <https://doi.org/10.1159/000069324>
2. Endo M. (1977). "Calcium release from the sarcoplasmic reticulum." *Physiol Rev* 57 (1): 71–108. <https://doi.org/10.1016/b978-012656975-9/50028-6>
3. Boshour T, Basha HS, Cheng TO: Hypocalcemic cardiomyopathy. *Chest* 1980; 78: 663-65. <https://doi.org/10.1378/chest.78.4.663>
4. Khardori R, Cohen B, Taylor D, Soler NG. Electrocardiographic finding simulating acute myocardial infarction in a compound metabolic aberration. *Am J Med* 1985; 78:529–32. [https://doi.org/10.1016/0002-9343\(85\)90351-1](https://doi.org/10.1016/0002-9343(85)90351-1)
5. Taddei, S, Caraccio, N, Virdis A. Impaired endothelium-dependent vasodilatation in subclinical hypothyroidism: beneficial effect of levothyroxine therapy. *J Clin Endocrinol Metab* 2003; 88:3731. <https://doi.org/10.1210/jc.2003-030039>
6. Klein, I, Ojamaa, K. Thyroid hormone and the cardiovascular system. *N Engl J Med* 2001; 344:501.
7. Thakker RV. Parathyroid disorders and diseases altering calcium metabolism. In: Warrall D, Cox T, Firth J, Benz E, eds. *Oxford textbook of medicine* 4th ed. Oxford: Oxford University Press, 2003.
8. Tohme, JF, Bilezikian, JP. Diagnosis and treatment of hypocalcemic emergencies. *The Endocrinologist*. 1996; 6:10. <https://doi.org/10.1097/00019616-199601000-00003>
9. Ozerkan F, Güngör H, Zoghi M, Nalbantgil S. Cardiac failure secondary to idiopathic hypoparathyroidism: a case report. *Turk Kardiyol Dern Ars* 2009 Jan;37(1):53-6.
10. Lam J, Maragaño P, Lépéz B, Vásquez L. Hypocalcemic cardiomyopathy secondary to hypoparathyroidism after a thyroidectomy: report of one case. *Rev Med Chil* 2007 Mar;135(3):359-64.
11. Behaghel A, Donal E. Hypocalcaemia-induced transient dilated cardiomyopathy in elderly: a case report. *Eur J Echocardiogr* 2011 Oct;12(10):E38. <https://doi.org/10.1093/ejechoard/jer105>
12. Sung JK, Kim JY, Ryu DW, Lee JW, Youn YJ, Yoo BS et al. A case of hypocalcemia-induced dilated cardiomyopathy. *J Cardiovasc Ultrasound* 2010 Mar;18(1):25-7. <https://doi.org/10.4250/jcu.2010.18.1.25>
13. Ari H, Ari S, Koca V, Bozat T. A rare cause of reversible dilated cardiomyopathy: hypocalcemia. *Turk Kardiyol Dern Ars* 2009 Jun;37(4):266-8. <https://doi.org/10.1111/j.0742-2822.2004.03149.x>
14. Avsar A, Dogan A, Tavli T. A rare cause of reversible dilated cardiomyopathy: hypocalcemia. *Echocardiography* 2004 Oct;21(7):609-12. <https://doi.org/10.1111/j.0742-2822.2004.03149.x>
15. Kini SM, Pednekar SJ, Nabar ST, Varthakavi P. A reversible form of cardiomyopathy. *J Postgrad Med* 2003 Jan-Mar;49(1):85-7. <https://doi.org/10.4103/0022-3859.919>

-
16. Fisher NG, Armitage A, McGonigle RJ, Gilbert TJ. Hypocalcaemic Cardiomyopathy; the relationship between myocardial damage, left ventricular function, calcium and ECG changes in a patient with idiopathic hypocalcaemia. *Eur J Heart Fail* 2001 Jun;3(3):373-6. [https://doi.org/10.1016/s1388-9842\(01\)00125-8](https://doi.org/10.1016/s1388-9842(01)00125-8)
 17. Sandow A. Excitation-Contraction Coupling in Muscular Response. *Yale J Biol Med* 25 (3): 176–201.
 18. Lionel H. Opie, Gerd Hasenfuss. Mechanisms of Cardiac Contraction and Relaxation. In: Robert O. Bonow, Douglas L. Mann, Douglas P. Zipes, Peter Libby. *Braunwald's Heart Disease*. Philadelphia: Elsevier Saunders; 2012.

Cardiomyopathy Secondary to Thyroid and Parathyroid Dysfunction: Case Report and Literature Review

Yousef Darrat, MD¹, Todd W. Gress MD, MPH², Ellen A. Thompson, MD², Paulette S. Wehner, MD, FACC, FCCP, FACP², Mitch Charles, MD, FACEP².

Author Affiliations:

1. University of Kentucky, Lexington, KY
2. Joan C Edwards School of Medicine, Marshall University, Huntington, West Virginia

The authors have no financial disclosures to declare and no conflicts of interest to report.

Corresponding Author:

Yousef Hadi Darrat, MD
University of Kentucky
900 S. Limestone St.
Lexington, KY 40536-0200
Email: yhda222@uky.edu

Abstract:

Heart failure due to metabolic derangements is not common in clinical practice. However, outcome is usually positive given that the precipitating factor is recognized and treatment is initiated in a timely fashion. We report an unusual case of reduced left ventricular systolic function in the setting of hypocalcemia in a patient without known structural heart disease. Delay in seeking appropriate medical attention has culminated in cardiac dysfunction that was favorably altered with correction of hypocalcemia.

Keywords: Cardiomyopathy, hypothyroidism, hypocalcemia, hypoparathyroidism

Introduction:

Most patients with cardiomyopathy have a poor prognosis due to progressive and irreversible myocardial dysfunction. Although some causes of cardiomyopathy are well known, such as toxic substances or viral infections, rarely, is there a reversible cause identified and the etiology is deemed idiopathic. The role of calcium in myocardial excitation contraction coupling has been well described but hypocalcemic cardiomyopathy due to hypoparathyroidism is an infrequently encountered condition. It is usually refractory to conventional treatment but responds favorably to restoration of normocalcemia. (1)

Cardiac dysfunction secondary to metabolic derangements should be considered in the differential diagnosis of heart failure in previously healthy patients who do not respond adequately to the usual treatment. Prompt recognition of the provoking factor is important since the disease process is potentially reversible. We report a case and discuss the mechanism of acute cardiomyopathy associated with hypocalcemia.

Case Report:

A 57 year old previously healthy white woman was found at home by her daughter having convulsions. A CT-scan of the head at a local emergency department (ED) was obtained with normal results. She was transferred to our center because of elevated cardiac enzymes. Subsequently she regained consciousness, reporting chest pain that was relieved by short acting nitroglycerin. She denied shortness of breath but reported dry cough and fatigue. The patient appeared distressed but was alert and oriented. Her blood pressure (BP) was 98/47 mmHg, heart rate regular 97 beats per minute, respiratory rate 28 per minute, temperature 96°F and oxygen saturation 92% on 4 liters of oxygen by nasal canula. Physical examination showed faint S1 and S2 without murmur; bilateral fine crepitations in all lung fields, and pitting lower limb edema. Chvostek's and Trousseau's sign (carpopedal spasm) were not elicited. The patient's past medical history was insignificant; no history of neck surgery or radiation as a reason for hypothyroidism or hypoparathyroidism, there was no history of alcohol abuse that may result in systolic dysfunction. Furthermore, tachycardia mediated cardiomyopathy was ruled out since there was no history of arrhythmia and none was identified during her hospital stay while she was on telemetry monitoring. Iron study performed to screen for hemochromatosis is within normal. There was no known family history of endocrine disorders.

Initial workup in the ED revealed a calcium level of 5mg/dl (refer to Table 1 for laboratory results). A 12 lead electrocardiogram (EKG) (Figure 1) demonstrated T-wave inversion along with a prolonged QT interval (QTc= 0.693 sec using Bazett's formula). Urine drug screen including cocaine was negative.

Table 1: Laboratory results

Laboratory	Value	Range
Calcium	5 mg/dl	8.5-10.5 mg/dl
Ionized calcium	0.65 mmol/l	1.12-1.38 mmol/l
Phosphorus	8.2 mg/dl	2.5-4.5 mg/dl
Magnesium	1.7 mg/dl	1.6-2.4 mg/dl
Parathyroid hormone	2.5 pg/ml	(8-97 pg/ml)
25, Hydroxy vitamin D	8 ng/ml	(32-100ng/ml)
TSH	21.48 miliU/L	0.370-4.420 miliU/L
Free T4	0.62 ng/dl	0.75-2
Troponin	9.3	0.0-0.5
Total CK	13983	55-170
CKMB	77.1	0.0-5
Myoglobin	>1000	0-110
Creatinine	1.6 mg/dl	0.7-1.4
BUN	19mg/dl	7-21 mg/dl

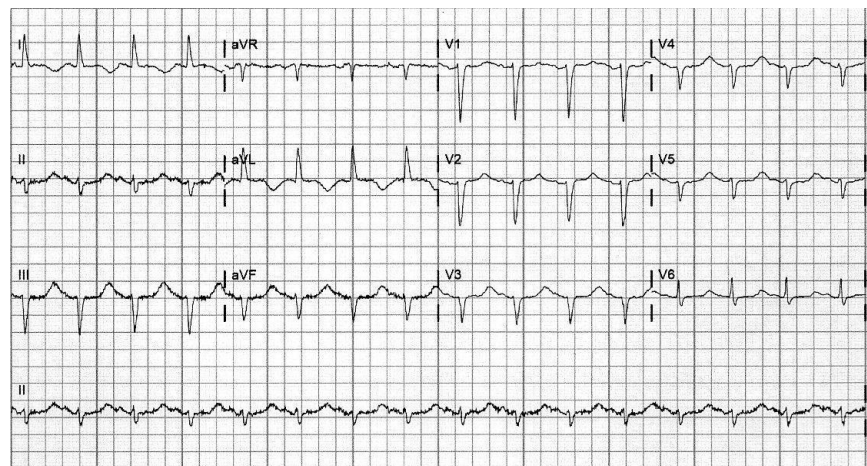


Figure 1: Electrocardiogram demonstrating prolonged corrected QT interval (QTc= 0.693 second using Bazett's formula) and T-wave inversion in leads I and AVL.

Her chest X-ray showed pulmonary edema (Figure 2). Echocardiogram demonstrated a globally hypokinetic left ventricle with severely depressed left ventricular ejection fraction of 25-30% without evidence of left ventricular hypertrophy or significant valvular lesions. Subsequent cardiac catheterization revealed no angiographic evidence of obstructive coronary artery disease.

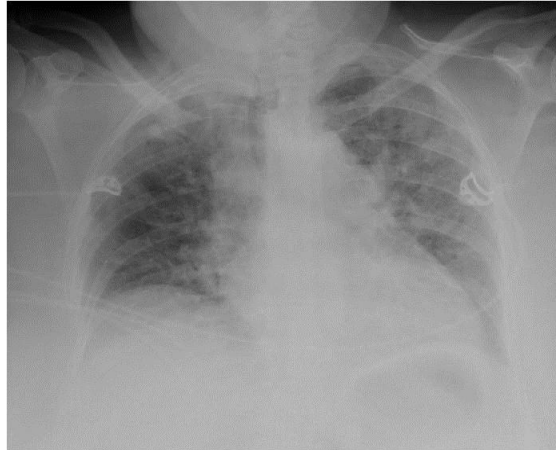


Figure 2: Chest X-ray demonstrating bilateral interstitial infiltrate consistent with pulmonary edema.

The patient initially received a single dose of intravenous calcium gluconate of 1000 milligrams given slowly to reverse the acute effects of hypocalcemia including seizures. The levels of ionized calcium were closely followed and a dose of calcium chloride 1000 milligrams was subsequently administered via central line resulting in the correction of serum calcium. The patient's symptoms started to subside, hemodynamic status improved and EKG changes resolved after serum calcium was normalized (Figure 3). Endocrinology service was consulted to provide advice on treating hypothyroidism and hypoparathyroidism. The patient was started on oral supplementation of calcium carbonate and vitamin D (1,25-dihydroxycholecalciferol) and was also started on thyroid replacement therapy. She remained asymptomatic and was discharged home in a stable condition. Unfortunately, the patient was lost to cardiology follow-up, and her long-term clinical course is unknown.

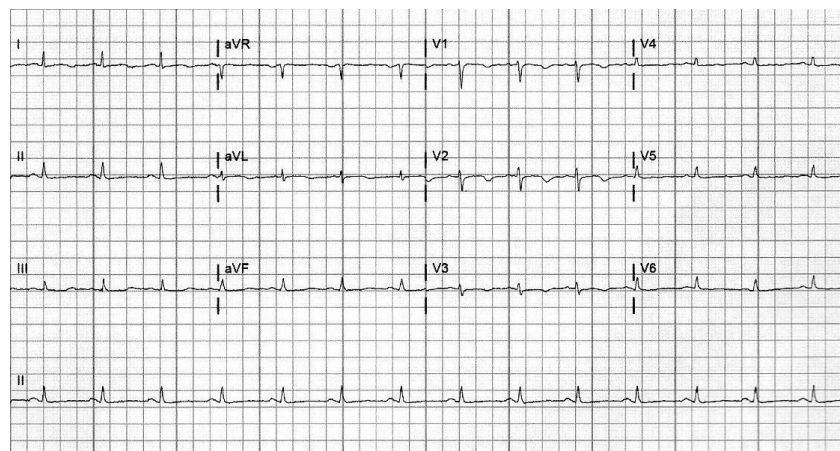


Figure 3: Electrocardiogram demonstrating normalization of corrected QT interval ($QT_c = 0.41$ second using Bazett's formula) and resolution of previously noted T wave inversion.

Discussion:

This unique case demonstrates acute cardiomyopathy precipitated by metabolic derangement in the absence of other obvious etiologies.

It is well established that calcium ions play a central role in myocardial excitation contraction coupling (Figure 4) and myocardial relaxation. (2) Once the intracellular concentration of calcium increases, calcium ions bind to the protein troponin which initiates contraction by allowing the contractile proteins, myosin and actin, to associate through cross-bridge formation. An inward flux of extracellular calcium ions through L-type calcium channels a voltage dependent calcium channel, sustains the depolarization of cardiac muscle cells for a longer duration. (2) Therefore, hypocalcemia may cause cardiac dysfunction that usually does not respond to positive inotropic and diuretic therapies. While moderate reduction of serum calcium for a limited period of time may not result in a clinically appreciable decrease in myocardial function, it appears that profound and prolonged hypocalcemia may result in secondary cardiomyopathy manifested clinically by congestive heart failure that is responsive only to normalization of serum calcium. (3) Several cases have been reported in medical literature demonstrating the restoration of cardiac function after correction of serum calcium levels (Table 2).

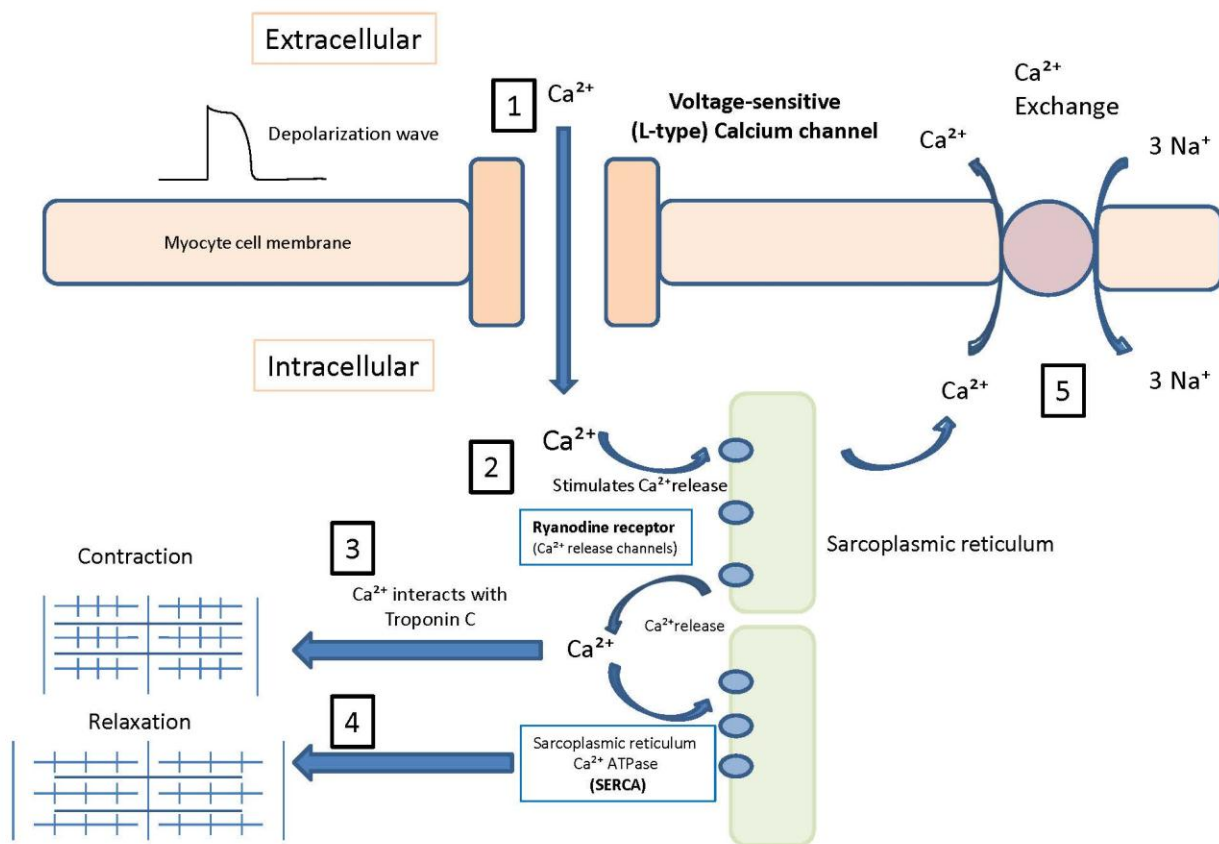


Figure 4: The role of calcium in systole and diastole at cellular level. 1) Calcium enters via L-type calcium channels following depolarization. 2) Entering calcium stimulates the release of calcium via Ryanodine receptors on sarcoplasmic reticulum. 3) Calcium interacts with Troponin C initiating contraction (systole). 4) Calcium uptake via SERCA results in relaxation (diastole). 5) Calcium is extruded outside myocyte via $\text{Na}^+/\text{Ca}^{2+}$ exchanger (17, 18).

Table 2: Case reports of hypocalcemic cardiomyopathy illustrating the impact of hypocalcemia on cardiac function and the improvement in systolic and/or diastolic function with normocalcemia.

Author	Patient's age (years)	Clinical Presentation	Calcium level (mg/dl)	EF	Diagnosis	Response
Ozerkan et al. (9)	40	CHF, NYHA class III	6.3	25%	Primary hypoparathyroidism	LVEF improved
Lam et al. (10)	37	CHF	2.9	Systolic and diastolic dysfunction	Iatrogenic hypoparathyroidism	Persistence of systolic and diastolic dysfunction
Behaghel et al. (11)	76	CHF	4.8	36%	Iatrogenic hypoparathyroidism	Normalization of systolic function after 2 months
Sung et al. (12)	57	CHF, NYHA class III	5.16	37%	Iatrogenic hypoparathyroidism	EF improved to 61%
Ari H et al. (13)	27	CHF	2.9	20-25%	Vitamin D resistant rickets	EF improved to 55%
Avsar et al. (14)	40	CHF	3.5	25%	Iatrogenic hypoparathyroidism	EF improved to normal
Kini et al. (15)	30	CHF	3.03	20%	Primary hypoparathyroidism	Clinically improved but EF at 35% after 40 months
Fisher et al. (16)	38	Atypical chest pain, ischemic EKG changes	6.8	37%	Iatrogenic hypoparathyroidism	Normalization of LVEF after 3 months

Our patient had EKG changes that were resolved after correction of the serum calcium. The EKG changes could be explained by coronary artery spasm, known to occur with hypomagnesemia, which in turn is often associated with hypocalcemia. (4)

The deficiency of thyroid hormones can be also connected with a range of metabolic and hemodynamic changes that can contribute to the genesis of heart failure. The major cardiovascular changes that occur in hypothyroidism include decreased cardiac contractility, reduced heart rate, and increased peripheral vascular resistance. (5, 6)

The history and laboratory findings in this patient suggest that hypocalcemia, secondary to hypoparathyroidism, in the presence of unrecognized and untreated hypothyroidism have predisposed to acute decompensation of heart failure. Attributing acute myocardial dysfunction to hypocalcemia in this case is justified by several explanations. First, the patient demonstrated rapid clinical improvement upon administration of calcium without the use of inotropic agents or diuretics. Second, supplementation with thyroid replacement therapy does not usually result in prompt reversal of metabolic events. Third, although the most common reason for impaired cardiac function is ischemic heart disease, the presence of normal coronary angiogram excluded significant atherosclerosis as the underlying cause. Fourth, there was an absence of usual etiologies of systolic dysfunction including alcoholism, long standing tachycardia, cocaine abuse and structural heart disease.

Symptomatic patients presenting with neuromuscular irritability secondary to hypocalcaemia or asymptomatic patients with corrected serum calcium of less than 7.5 mg/dl are treated with intravenous calcium gluconate. (7) Calcium gluconate (10 ml of 10%) can be slowly infused over 10-20 minutes. (7) It is preferred over calcium chloride which may cause local irritation. Calcium should not be infused rapidly due to risk of dysarrhythmias and cardiac arrest. (8) Infusion of calcium can be repeated until symptoms have resolved. Oral calcium replacement should be given concurrently and a vitamin D analogue added if parathyroid hormone is deficient (7) as in this case.

Conclusion:

Hypocalcemia secondary to hypoparathyroidism is a rare cause of heart failure in adults, and is curable after administration of calcium. It can be overlooked, although easily diagnosed and treated.

It is important to consider metabolic derangement in patients with symptoms of heart failure of unidentified cause, as it is potentially reversible.

References:

1. Altunbaş H, Balci MK, Yazicioğlu G, Semiz E, Ozbilim G, Karayalçın U. Hypocalcemic cardiomyopathy due to untreated hypoparathyroidism. *Hormone Research* 2003; 59(4):201-4.
2. Endo M. (1977). "Calcium release from the sarcoplasmic reticulum." *Physiol Rev* 57 (1): 71–108.
3. Boshour T, Basha HS, Cheng TO: Hypocalcemic cardiomyopathy. *Chest* 1980; 78:663-65.
4. Khardori R, Cohen B, Taylor D, Soler NG. Electrocardiographic finding simulating acute myocardial infarction in a compound metabolic aberration. *Am J Med* 1985; 78:529–32.
5. Taddei, S, Caraccio, N, Virdis A. Impaired endothelium-dependent vasodilatation in subclinical hypothyroidism: beneficial effect of levothyroxine therapy. *J Clin Endocrinol Metab* 2003; 88:3731.
6. Klein, I, Ojamaa, K. Thyroid hormone and the cardiovascular system. *N Engl J Med* 2001; 344:501.
7. Thakker RV. Parathyroid disorders and diseases altering calcium metabolism. In: Warrall D, Cox T, Firth J, Benz E, eds. *Oxford textbook of medicine* 4th ed. Oxford: Oxford University Press, 2003.
8. Tohme, JF, Bilezikian, JP. Diagnosis and treatment of hypocalcemic emergencies. *The Endocrinologist*. 1996; 6:10.
9. Ozerkan F, Güngör H, Zoghi M, Nalbantgil S. Cardiac failure secondary to idiopathic hypoparathyroidism: a case report. *Turk Kardiyol Dern Ars* 2009 Jan;37(1):53-6.
10. Lam J, Maragaño P, Lépez B, Vásquez L. Hypocalcemic cardiomyopathy secondary to hypoparathyroidism after a thyroidectomy: report of one case. *Rev Med Chil* 2007 Mar;135(3):359-64.
11. Behaghel A, Donal E. Hypocalcaemia-induced transient dilated cardiomyopathy in elderly: a case report. *Eur J Echocardiogr* 2011 Oct;12(10):E38.
12. Sung JK, Kim JY, Ryu DW, Lee JW, Youn YJ, Yoo BS et al. A case of hypocalcemia-induced dilated cardiomyopathy. *J Cardiovasc Ultrasound* 2010 Mar;18(1):25-7.
13. Ari H, Ari S, Koca V, Bozat T. A rare cause of reversible dilated cardiomyopathy: hypocalcemia. *Turk Kardiyol Dern Ars* 2009 Jun;37(4):266-8.
14. Avsar A, Dogan A, Tavli T. A rare cause of reversible dilated cardiomyopathy: hypocalcemia. *Echocardiography* 2004 Oct;21(7):609-12.
15. Kini SM, Pednekar SJ, Nabar ST, Varthakavi P. A reversible form of cardiomyopathy. *J Postgrad Med* 2003 Jan-Mar;49(1):85-7.
16. Fisher NG, Armitage A, McGonigle RJ, Gilbert TJ. Hypocalcaemic Cardiomyopathy; the relationship between myocardial damage, left ventricular function, calcium and ECG changes in a patient with idiopathic hypocalcaemia. *Eur J Heart Fail* 2001 Jun;3(3):373-6.
17. Sandow A. Excitation-Contraction Coupling in Muscular Response. *Yale J Biol Med* 25 (3): 176–201. *Yale J Biol Med* 1952 December; 25(3): 176–201.
18. Lionel H. Opie, Gerd Hasenfuss. Mechanisms of Cardiac Contraction and Relaxation. In: Robert O. Bonow, Douglas L. Mann, Douglas P. Zipes, Peter Libby. *Braunwald's Heart Disease*. Philadelphia: Elsevier Saunders; 2012.