

2-2019

Massive hemoptysis due to recurrence of bronchial to pulmonary vascular malformation: A case report

Chelsey White

Marshall University, ayers23@live.marshall.edu

Pedro Ottaviano

Marshall University, ottavianop@marshall.edu

Nancy Munn

Marshall University, munn@marshall.edu

Yousef Shweihat

Marshall University, shweihat@marshall.edu

Fuad Zeid

Marshall University, zeid@marshall.edu

Follow this and additional works at: https://mds.marshall.edu/int_med



Part of the [Internal Medicine Commons](#)

Recommended Citation

White, C., Ottaviano, P., Munn, N., Shweihat, Y. and Zeid, F. Massive hemoptysis due to recurrence of bronchial to pulmonary vascular malformation: A case report. *Respiratory Medicine Case Reports*. 2019;26:248-50.

This Article is brought to you for free and open access by the Faculty Research at Marshall Digital Scholar. It has been accepted for inclusion in Internal Medicine by an authorized administrator of Marshall Digital Scholar. For more information, please contact zhangj@marshall.edu, beachgr@marshall.edu.



Case report

Massive hemoptysis due to recurrence of bronchial to pulmonary vascular malformation: A case report

Chelsey White^{a,b,*}, Pedro Ottaviano^{a,b}, Nancy Munn^{a,b}, Yousef Shweihat^{a,b}, Fuad Zeid^{a,b}

^a Joan C. Edwards Marshall School of Medicine, Huntington, WV, USA

^b Huntington Veterans Administration Medical Center, Huntington, WV, USA

ARTICLE INFO

Keywords:

Bronchial dieulafoy
Hemoptysis
Vascular malformation

ABSTRACT

Bronchial dieulafoy lesions are quite rare with relatively few case reports in the literature. Symptoms may vary but the lesion is often associated with hemoptysis and may present as massive hemoptysis. We present a case of a 69-year-old male with a recurrent episode of hemoptysis three years after treatment for a bronchial dieulafoy lesion. The bronchoscopy done three years prior during an initial episode of hemoptysis showed a visible dieulafoy deep within a subsegmental branch of the right lower lobe. This case is unique because there are no other reports within the literature of a delayed recurrence several years after previous treatment of a bronchial dieulafoy lesion, which in our case was due to bronchial to pulmonary vascular malformation. Bronchial arteriography revealed a bronchial artery to pulmonary artery vascular malformation, which was successfully treated with coil embolization.

1. Introduction

Hemoptysis is a concerning and often life-threatening symptom if massive. Though etiology and severity varies, close monitoring and prompt diagnosis are required. A rare cause of hemoptysis, with only a few reported cases, is a bronchial dieulafoy malformation. Dieulafoy lesions are more commonly seen within the gastrointestinal tract and are rarely a cause of bronchial bleeding. Bronchoscopic diagnosis is crucial, as biopsy of a vascular malformation is often fatal.

2. Case presentation

A 69-year-old obese male, never smoker, presented with hemoptysis. He had a past medical history of diabetes mellitus, obstructive sleep apnea, hypertension and chronic kidney disease. Three years prior to his current presentation, he had an initial episode of hemoptysis. At that presentation, he had no evidence of hemodynamic compromise or respiratory failure. He underwent bronchoscopy, which showed large clots extending into the right bronchus intermedius. After removal of clots, a visible, tortuous, and minimally bleeding vessel was noted within the posterior subsegment of the lateral segment of the right lower lobe. The lesion was treated locally with epinephrine injection and the patient had no recurrence of bleeding until the most recent admission. He did not undergo angiography with embolization at that time due to cessation of hemoptysis and presence of acute kidney

injury. At the time of his recent admission to the hospital the patient was hemodynamically stable without evidence of hypoxia. His episode of hemoptysis occurred the night prior to his admission and he had no other episodes of hemoptysis until 12 hours after his admission. CT of the chest with IV contrast was negative for pulmonary embolism and showed a right lower lobe infiltrate (*Image 1*). He was taken for bronchoscopy, which showed extensive clots extending from the bronchus intermedius into the right lower lobe (*Image 2*). Bleeding was localized to the lateral segment of the right lower lobe but a definitive lesion was unable to be identified. He was intubated for airway protection and transferred to the interventional radiology suite. Further imaging with bronchial arteriography showed an arteriovenous malformation of a branch of the right lower lobe bronchial artery, for which coil embolization using 5 microcoils was performed (*Image 3*). At follow up 6 months later, he had no recurrent episodes of hemoptysis.

3. Discussion

Massive hemoptysis is often life threatening. Unfortunately, in up to 25% of cases a cause is unidentified. Our case highlights an unusual source of hemoptysis due to a bronchial dieulafoy. Prompt diagnosis and treatment are prudent, as bleeding can be severe or even fatal. This case is rare in that the patient had bronchoscopic treatment 3 years before developing recurrence.

* Corresponding author. Joan C. Edwards Marshall School of Medicine, Huntington, WV, USA.

E-mail address: ayers23@live.marshall.edu (C. White).

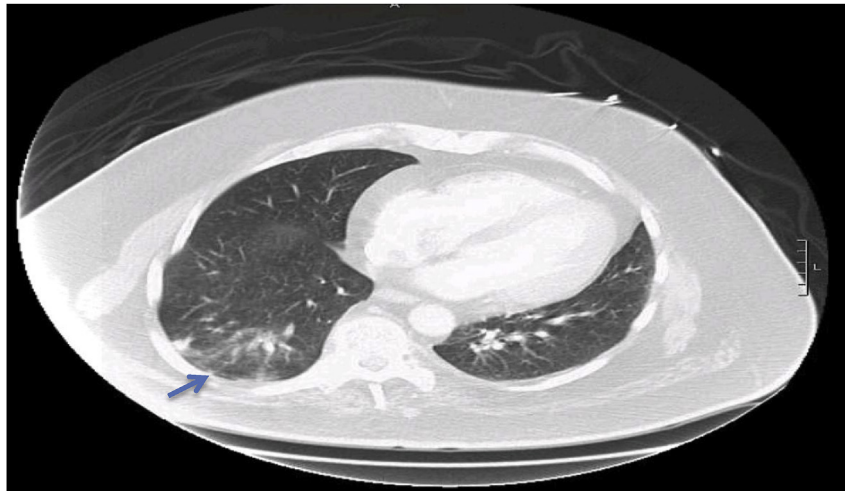


Image 1. CT chest with IV contrast taken at presentation of massive hemoptysis showing right lower lobe infiltrate.

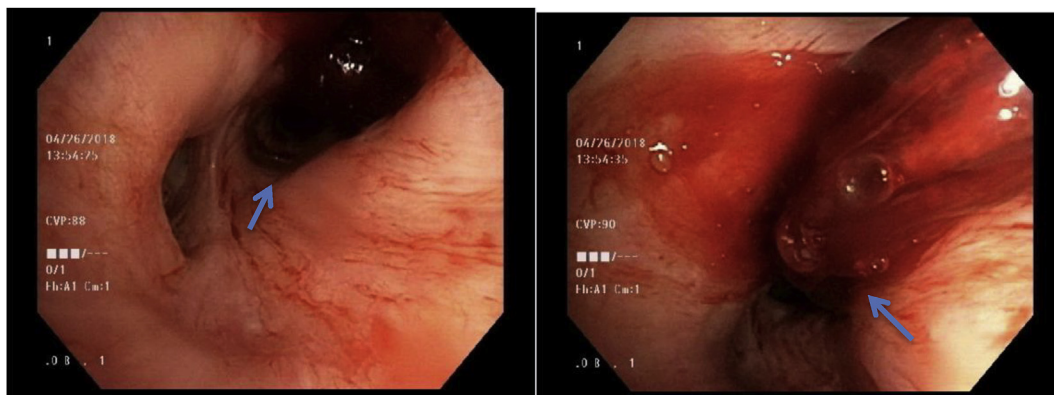


Image 2. Bronchoscopy images at presentation of recurrence of hemoptysis showing clot formation in right lower lobe opening (left) and active bleeding from right lower lobe lateral segment (right). Due to active bleeding, visualization of exact source could not be identified.

A Dieulafoy is a vascular malformation described as a dilated, tortuous artery which protrudes into the submucosa. Dieulafoy's disease was initially described as a source of bleeding within the gastrointestinal tract, but a bronchial dieulafoy is a rare cause of hemoptysis and often difficult to detect [2]. Though exact etiology is unknown, it has been hypothesized to be a congenital anomaly [1,3]. There have been few reported cases in adolescents, suggesting congenital etiology. Our patient had a bronchial artery to pulmonary artery vascular malformation. Surprisingly, Osler-Weber- Rendu disease has not been identified as a cause when systemic vasculature is involved [1]. Pulmonary arteriovenous malformations arising from the systemic circulation are rare, especially those arising from a bronchial artery [1].

The anomalous arteries in dieulafoy lesions can originate from either the pulmonary or bronchial arteries [1]. Fang and colleagues noted 9 of 17 cases of arterioles branching from the bronchial artery and 3 of 17 from the pulmonary artery. The remaining cases were unable to be localized.

Previous cases have noted that heavy smoking and increased age are risk factors for bleeding [2,10]. There are several factors that may contribute to bleeding of a bronchial dieulafoy, most commonly iatrogenic injury such as from bronchoscopy or biopsy. Other contributing factors include those with underlying respiratory conditions, including a history of tuberculosis, frequent pneumonia, chronic bronchitis, and bronchiectasis [3].

For diagnosis, angiography is useful for the identification of bronchial Dieulafoy and in cases of recurrent hemoptysis. Bronchoscopy can also be used, though distal lesions, as in our case, are not always

identifiable. Visibility of a lesion is often limited based on location or presence of clot or pooling of blood. If the lesion is seen, it often appears as a cone shaped endobronchial protrusion. Caution is advised to prevent fatal hemoptysis secondary to biopsy. Biopsy of a dieulafoy lesion can be lethal if mistaken for a submucosal lesion [3]. Other techniques, such as endobronchial ultrasound, have been used to successfully identify suspected dieulafoy lesions when they are in a more proximal location.

Treatment of a bronchial dieulafoy depends on location of lesion, presentation and local expertise. As demonstrated in prior case reports, angiography with arterial embolization is recommended, which was used for our patient with a successful outcome [9]. In the case of failed embolization attempts by technical failures or unsuccessful cannulations, surgical resection may be required [4]. Additional treatment modalities have also been used such as cauterization or argon plasma coagulation [5,6] and cryotherapy [8].

In our case, the bleeding dieulafoy lesion was identified with bronchoscopy 3 years prior. Bleeding was controlled by local injection of epinephrine at the site of the visibly bleeding vessel. In the initial presentation, the patient had acute kidney injury thus angiography was avoided due to cessation of bleeding after treatment. Angiography with embolization is the standard treatment for hemoptysis due to arteriovenous malformations, though in certain circumstances may not be preferred. Bronchoscopic techniques including cold saline, epinephrine injection and cautery are also used in identifiable lesions to achieve hemostasis, which are also techniques used to control bleeding from gastrointestinal dieulafoy lesions [7]. Endoscopic techniques have been

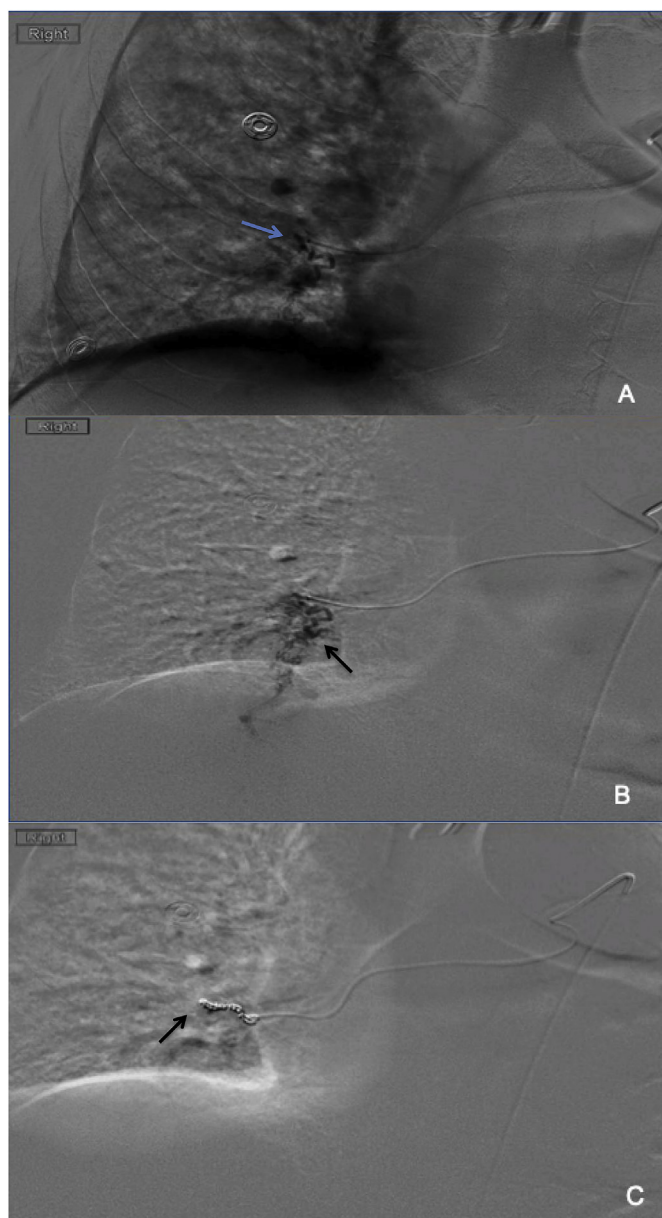


Image 3. Images from interventional radiology showing right lower lobe bronchial artery to pulmonary artery vascular malformation (A, B). Image C shows successful coil embolization of right lower lobe bronchial artery.

rarely reported as a successful treatment modality. As reported by Stoppen, cauterization was a temporizing measure that ultimately required lobectomy [6]. Though recurrence did ultimately occur in our case, there are no other case reports in which cauterization or bronchoscopic intervention was successful for a significant period of time [12]. Those who have recurrence after bronchial artery embolization are most often due to aberrant pulmonary artery rather than bronchial artery, bronchopulmonary shunts and revascularization [4].

Our case was unusual in that the patient had recurrence of bleeding several years after treatment without obvious predisposing or precipitating factors. Recurrence after bronchial arterial embolization is not uncommon, yet as previously reported by Bhatia and colleagues,

recurrence was often noted within 0–2 years after treatment [13]. For cases of recurrent hemoptysis, repeated angiography with embolization is recommended prior to proceeding with surgical treatment, due to the lower complication rate and morbidity when compared with lobectomy [4].

4. Conclusion

Bronchial dieulafofy lesions are a rare but serious cause of hemoptysis. Even in those without risk factors, there should be a high index of suspicion when other more common causes of hemoptysis are not apparent [11]. Caution should be used during bronchoscopy when investigating cause of hemoptysis, as biopsy of such a vascular lesion can be lethal. As noted with our case, a recurrence of bleeding can occur even without obvious inciting event and after previously undergoing treatment. Thus, regular monitoring for further bleeding is recommended post therapy in patients with Dieulafofy lesions. Further studies to investigate potential contributing factors would be beneficial. This case describes the successful management of a rare cause of recurrent hemoptysis using bronchial arteriography with embolization.

Conflicts of interest

The authors have no conflicts of interest to disclose.

References

- [1] H.M.M. Pouwels, et al., Systemic to pulmonary vascular malformation, *Eur. Respir. J.* 5 (1992) 1288–1291.
- [2] Ben Smith, et al., Dieulafofy's disease of the bronchus: a rare cause of massive hemoptysis, *Respirol. Case Rep.* 2 (2) (June 2014) 55–56, Accessed date: 12 October 2018.
- [3] Yu Fang, et al., Dieulafofy's disease of the bronchus: report of a case and review of the literature, *J. Cardiothorac. Surg.* 9 (1) (2 Dec. 2014) 1, <https://doi.org/10.1186/s13019-014-0191-8>, Accessed date: 12 October 2018.
- [4] Oormila Ganganah, et al., Endobronchial ultrasound and bronchial artery embolization for Dieulafofy's disease of the bronchus in a teenager: a case report, *Respir. Med. Case Rep.* 16 (2015) 20–23, <https://doi.org/10.1016/j.rmcr.2015.04.007>, Accessed date: 12 October 2018.
- [5] Karan Madan, et al., Flexible bronchoscope argon plasma coagulation for management of massive hemoptysis in bronchial Dieulafofy's disease, *Lung India* 34 (1) (2017) 99–101, <https://doi.org/10.4103/0970-2113.197096>, Accessed date: 12 October 2018.
- [6] E. Stoopen, et al., Dieulafofy's disease of the bronchus in association with a paravertebral neuilemoma, *Chest* 119 (1) (Jan. 2001) 292–294, <https://doi.org/10.1378/chest.119.1.292>, Accessed date: 12 October 2018.
- [7] Antoine Parrot, et al., Approach to diagnosis and pathological examination in bronchial Dieulafofy disease: a case series, *Respir. Res.* 9 (1) (Aug. 2008) 58, <https://doi.org/10.1186/1465-9921-9-58>, Accessed date: 12 October 2018.
- [8] Esther L. Fields, Dominic R. de Keratry, Dieulafofy disease of the bronchus: case report and presentation of a novel therapeutic modality, *J. Bronchol. Interv. Pulmonol.* 15 (2) (Apr. 2008) 107–109, <https://doi.org/10.1097/LBR.0b013e318169eef4>, Accessed date: 12 October 2018.
- [9] Danrong Yang, et al., Dieulafofy disease of the trachea with recurrent episodes of massive hemoptysis, *Med. (Baltim.)* 96 (5) (Feb. 2017) e5855, <https://doi.org/10.1097/MD.0000000000005855>, Accessed date: 12 October 2018.
- [10] M.B. Wadji, A. Farahzadi, Dieulafofy's disease of the bronchial tree: a case report, *San Paulo Med. J.* 135 (4) (29 May 2017) 396–400, <https://doi.org/10.1590/1516-3180.2016.0258191116>, Accessed date: 12 October 2018.
- [11] Akin Kuzucu, et al., Dieulafofy's disease: a cause of massive hemoptysis that is probably underdiagnosed, *Ann. Thorac. Surg.* 80 (2005) 1126–1128, <https://doi.org/10.1016/j.athoracsur.2004.02.118>, Accessed date: 12 October 2018.
- [12] Hardik S. Sheth, et al., Two cases of Dieulafofy lesions of the bronchus with novel comorbid associations and endobronchial ablative management, *Medicine (Baltim.)* 97 (8) (Feb. 2018) e9754, <https://doi.org/10.1097/MD.0000000000009754>, Accessed date: 12 October 2018.
- [13] Praveen Bhatia, M.S. Hendy, E. Li-Kam-Wa, P.K. Bowyer, Recurrent embolotherapy in Dieulafofy's disease of the bronchus, *Can. Respir. J.* 10 (6) (2003) 331–333 <https://doi.org/10.1155/2003/729714>.