

Marshall University

Marshall Digital Scholar

Internal Medicine

Faculty Research

5-16-2019

Should a fully covered self-expandable biliary metal stent be anchored with a double-pigtail plastic stent? A retrospective study

Saad Emhmed Ali


Wesam M. Frandah

Leon Su

Cory Fielding

Houssam Mardini

Follow this and additional works at: https://mds.marshall.edu/int_med

 Part of the [Analytical, Diagnostic and Therapeutic Techniques and Equipment Commons](#), and the [Internal Medicine Commons](#)

Retrospective Study

Should a fully covered self-expandable biliary metal stent be anchored with a double-pigtail plastic stent? A retrospective study

Saad Emhmed Ali, Wesam M Frandah, Leon Su, Cory Fielding, Houssam Mardini

ORCID number: Saad Emhmed Ali (0000-0002-3481-0365); Wesam M Frandah (0000-0001-8068-7030); Leon Su (0000-0001-7654-9997); Cory Fielding (0000-0002-8328-6731); Houssam Mardini (0000-0002-1090-5159).

Author contributions: Saad Emhmed Ali, Mardini H, Frandah WM and Cory Fielding C made the study design, data collection, and script preparation. Su L and Mardini H made the data analysis. Emhmed Ali SM, Frandah WM and Mardini H wrote the manuscript. Mardini H and Frandah WM was the reviewers of the paper.

Institutional review board

statement: This study was approved by the Ethics Committee of the University of Kentucky Medical Center, No: 17-0287-X6B.

Informed consent statement:

Patients were not required to give informed consent to the study because the analysis used anonymous data that were obtained after each patient agreed to treatment by written consent.

Conflict-of-interest statement: The authors declare no conflicts of interest.

Data sharing statement: No additional data are available.

Open-Access: This article is an open-access article which was selected by an in-house editor and fully peer-reviewed by external reviewers. It is distributed in accordance with the Creative

Saad Emhmed Ali, Department of Internal Medicine, Division of Hospital Medicine, Department of Internal Medicine, University of Kentucky, Lexington, KY 40536, United States

Wesam M Frandah, Cory Fielding, Houssam Mardini, Department of Internal Medicine, Division of Gastroenterology, Department of Internal Medicine, University of Kentucky, Lexington, KY 40536, United States

Leon Su, Department of Statistics, College of Arts and Sciences, College of Public Health, University of Kentucky, Lexington, KY 40536, United States

Corresponding author: Saad Emhmed Ali, MD, Assistant Professor, Internal Medicine Physician, Department of Internal Medicine, Division of Hospital Medicine, Department of Internal Medicine, University of Kentucky, 800 Rose St, Lexington, KY 40536, United States. saad.ali@uky.edu

Telephone: +1-859-2184991

Fax: +1-859-2283352

Abstract**BACKGROUND**

The migration rate of fully covered self-expandable metal stents (FCSEMSs) has been reported to be between 14% to 37%. Anchoring of FCSEMSs using a double-pigtail plastic stent (DPS) may decrease migration.

AIM

To compare stent migration rates between patients who received FCSEMS alone and those who received both an FCSEMS and anchoring DPS.

METHODS

We conducted a retrospective analysis of endoscopy reporting system and medical records of 1366 patients who underwent endoscopic retrograde cholangiopancreatography (ERCP) with FCSEMS placement at the University of Kentucky health care. Between July 2015 and April 2017, 203 patients with FCSEMS insertion for the treatment of malignant biliary stricture, benign biliary stricture, post-sphincterotomy bleeding, bile leak, and cholangitis drainage were identified. The review and analysis were conducted through our endoscopy reporting system (ProVation® MD) and medical records. Categorical data were analyzed using Chi-Square and Fischer exact test and continuous data using non-parametric tests. A regression analysis was performed to identify factors independently associated with increased risk of stent migration. We determined

Commons Attribution Non Commercial (CC BY-NC 4.0) license, which permits others to distribute, remix, adapt, build upon this work non-commercially, and license their derivative works on different terms, provided the original work is properly cited and the use is non-commercial. See: <http://creativecommons.org/licenses/by-nc/4.0/>

Manuscript source: Unsolicited manuscript

Received: March 6, 2019

Peer-review started: March 8, 2019

First decision: April 13, 2019

Revised: April 30, 2019

Accepted: May 10, 2019

Article in press: May 11, 2019

Published online: May 16, 2019

P-Reviewer: Gurkan A, Fiori E, Goral V, Osawa S, Fogli L

S-Editor: Dou Y

L-Editor: A

E-Editor: Xing YX



an FCSEMS migration endoscopically if the stent was no longer visible in the major papilla.

RESULTS

1366 patients had undergone ERCP by three advanced endoscopists over 21-mo period; among these, 203 patients had FCSEMSs placed. 65 patients had FCSEMSs with DPS, and 138 had FCSEMSs alone. 65 patients had FCSEMSs with DPS, and 138 had FCSEMSs alone. 95 patients had a malignant stricture, 82 patients had a benign stricture, 12 patients had bile leak, 12 patients had cholangitis, and nine patients had post-sphincterotomy bleeding. The migration rate in patients with anchored FCSEMSs with DPS was 6%, and those without anchoring DPS was 10% ($P = 0.35$). Overall, migration was reported in 18 patients with FCSEMSs placement out of 203 patients with an overall migration rate of 9.7%. There was no significant association between anchoring the FCSEMSs with DPS and the risk of stent migration. Only patients with the previous sphincterotomy and begin biliary stricture were found to have a statistically significant difference in the migration rate between patients who had FCSEMS with DPS and FCSEMS alone ($P = 0.01$).

CONCLUSION

The risk of migration of biliary FCSEMS was 9.7%. Anchoring an FCSEMS with DPS does not decrease the risk of stent migration.

Key words: Metal stents; Double-pigtail plastic stent; Endoscopic retrograde cholangiopancreatography; Biliary drainage; Biliary obstruction

©The Author(s) 2019. Published by Baishideng Publishing Group Inc. All rights reserved.

Core tip: In this study, we conducted a retrospective analysis to evaluate the efficacy of 7-French (Fr) and 10-Fr double-pigtail plastic stent (DPS) within the fully covered self-expandable metal stent (FCSEMS) as an anti-migration technique. We compared the rate of stent migration between patients who received FCSEMS alone and those who received both an FCSEMS and anchoring DPS in a large patient population with both benign and malignant strictures as well as non-stricture etiologies. Our findings suggest that anchoring of FCSEMS with a 7-Fr or 10-Fr DPS does not decrease the risk of stent migration. Only benign biliary stricture and previous sphincterotomy were to have a significant association with stent migrations ($P = 0.01$). We did not find evidence to support the routine placement of anchoring DPS.

Citation: Emhmed Ali S, Frandah WM, Su L, Fielding C, Mardini H. Should a fully covered self-expandable biliary metal stent be anchored with a double-pigtail plastic stent? A retrospective study. *World J Gastrointest Endosc* 2019; 11(5): 365-372

URL: <https://www.wjgnet.com/1948-5190/full/v11/i5/365.htm>

DOI: <https://dx.doi.org/10.4253/wjge.v11.i5.365>

INTRODUCTION

Fully covered self-expandable metal stents (FCSEMSs) have been widely used as an effective biliary endoprosthesis in the setting of pancreaticobiliary conditions such as benign and malignant strictures, post-sphincterotomy bleeding, and occasionally bile leaks^[1]. The primary advantages of covered stents are a lower rate of tumor ingrowth, longer patency, and their potential removability compared to uncovered stents. However, one concern about FCSEMSs is a higher migration rate than uncovered stents^[2]. The migration rate of FCSEMSs in prospective studies for benign biliary strictures is 5%-37%^[1]. In this study, we conducted a retrospective analysis to evaluate the efficacy of 7-French (Fr) and 10-Fr double-pigtail plastic stent (DPS) within the FCSEMS as an anti-migration technique. We compared the rate of stent migration between patients who received FCSEMS alone and those who received both an FCSEMS and anchoring DPS in a large patient population with both benign and malignant strictures as well as non-stricture etiologies.

MATERIALS AND METHODS

Between July 2015 and April 2017, 1366 patients had undergone endoscopic retrograde cholangiopancreatography (ERCP) at our institution. Among these, 203 patients with FCSEMS placement with or without DPS were identified. The review and analysis were conducted through our endoscopy reporting system (ProVation® MD) and medical records. Patients included in the study had FCSEMS insertion for the treatment of malignant biliary stricture, benign biliary stricture, and non-stricture etiology such as post-sphincterotomy bleeding and bile leak.

After the Institutional Review Board and the Ethics Committee of our hospital approved the study protocol, data was extracted by reviewing patient charts, ERCP reports, and fluoroscopic images. Patients who only had uncovered stents or plastic stents placed were excluded. All endoscopic procedures were performed by three advanced endoscopists. Comprehensive data were collected through Microsoft Excel spreadsheet and included the following: stent type [Wallflex™ (Boston Scientific) *vs* Viabil® (Gore Medical)], the diameter of double-pigtail PS (7-Fr *vs* 10-Fr), indications for FCSEMS placement including stricture type (malignant *vs* benign), and non-stricture etiologies such as post-sphincterotomy bleeding and bile leak.

Baseline patient characteristics were identified, such as previous cholecystectomy, biliary sphincterotomy, history of stent migration, choledocholithiasis, and diameter of the common bile duct (CBD). After stent placement and during the follow-up period, patients' records were reviewed to verify the stent position. We defined FCSEMS migration endoscopically if the stent was no longer visible through the major papilla. It either migrates proximally (into the bile duct) or distally (out of the bile of duct). The anti-migration properties of FCSEMSs include higher radial force, anchoring flap, anchoring fins and flared ends have been designed to prevent the migration. Categorical data were analyzed using the Chi-Square test and Fisher Exact test and continuous data using non-parametric tests. A regression analysis was performed to identify factors independently associated with increased risk of stent migration. All analyses were completed in SAS 9.4 (SAS Institute Inc., Cary, NC, United States).

The primary endpoint of the study was to compare stent migration rates between patients who received FCSEMSs alone and those who received both an FCSEMS with an anchoring DPS. A secondary endpoint was the presence of complications related to stent migration.

RESULTS

1366 patients had undergone ERCP by three advanced endoscopists over 21-mo period; among these, 203 patients had FCSEMS placed with or without DPS (88 females and 115 males). 65 patients had FCSEMSs with DPS, and 138 had FCSEMSs alone (Table 1 and Table 2). 95 patients had a malignant stricture, 82 patients had a benign stricture, 12 patients had bile leak, 12 patients had cholangitis, and nine patients had post-sphincterotomy bleeding (Figure 1). For the patients with stent migration, 12 (66.7%) had a benign biliary stricture, and 6 (33.3%) did not have, while for the patients without stent migration, 70 (37.8%) had a benign biliary stricture and 115 (62.2%) did not have ($P = 0.01$). Also, for patients with stent migration, 12 (66.7%) had the previous sphincterotomy, and 6 (33.3%) did not have, while for the patients without stent migration, 71 (38.4%) had the previous sphincterotomy and 114 (61.6%) did not have ($P = 0.01$). The migration rate in patients with benign biliary stricture was 14.6% and for those with non-benign biliary stricture was 5%. Migration rate in patients with the previous sphincterotomy was 14.5%, and those without previous sphincterotomy was 5%. Therefore, the distribution of patients that had a benign biliary stricture and previous sphincterotomy were significantly different between patients with stent migration and patients with no stent migration. There was no significant association between any of the other tested variables including anchoring the FCSEMSs with DPS and the risk of stent migration. The migration rate in patients with anchored FCSEMSs with DPS was 6%, and those without anchoring DPS was 10% ($P = 0.35$). Overall, migration was reported in 18 patients with FCSEMS placement out of 203 patients with an overall migration rate of 9.7%.

DISCUSSION

FCSEMS has been associated with longer patency than uncovered stents in some studies even though they may have higher rates of migration^[3-5]. To minimize the risk

Table 1 Clinical characteristics of patients who underwent fully covered self-expanding metal stent placement with or without double-pigtail plastic stent

Characteristic	Determinant	Frequency count	Percent of total frequency
Gender	Female	88	43.34
	Male	115	56.65
Race	Black	9	4.43
	White	194	95.56
Age	Mean (62.97); Range (23.00-91.00)		
Brand of FCSEMS	Viabil fully covered	90	44.33
	Viabil fully covered with proximal fenestration	63	31.03
	WallFlex	50	24.63
Cholangitis drainage	No	191	94.08
	Yes	12	5.91
Choledocholithiasis at time of stent placement	No	188	92.61
	Yes	15	7.38
History of cholecystectomy	No	92	45.32
	Yes	111	54.67
History of stent migration	No	196	96.55
	Yes	7	3.44
Length of FCSEMS (cm)	4	30	14.77
	6	106	52.21
	8	47	23.15
	10	20	9.85
Length of Stricture (mm)	Mean (19.21); Range (0.00-90.00)		
CBD diameter (mm)	Mean (11.19); Range (3.00-35.00)		
Malignant stricture	No	108	53.20
	Yes	95	46.79
Migration	No	185	91.13
	Yes	18	8.86
Post sphincterotomy bleed	No	194	95.56
	Yes	9	4.43
Previous sphincterotomy	No	120	59.11
	Yes	83	40.88
Sphincterotomy at time of stent deployment	No	82	40.39
	Yes	121	59.60

FCSEMS: Fully covered self-expanding metal stent; DPS: Double-pigtail plastic stent.

of migration, FCSEMSs have been designed with anti-migration mechanical properties, such as higher radial force, an anchoring flap, and specific stent flare structures⁶⁻⁸. Nevertheless, other modifications such as anchoring fins and flared ends have been designed to prevent the migration of FCSEMSs, even though; there are no randomized studies to evaluate their effectiveness^{7,9}.

In our study, the risk of migration of biliary FCSEMS seemed to be lower than previous studies at 9.7%. In contrast, migration rates have been reported to be up to 37.5% in the previous study¹¹. To our knowledge, there are only two studies that have evaluated the efficacy of anchoring DPS to prevent migration of FCSEMS.

In a randomized controlled study, Park *et al*^[10] described their experience of placing a 5-Fr DPS into FCSEMS in 17 patients out of 33 patients who received FCSEMS for benign biliary strictures. During the follow-up, the migration rate was significantly lower in the anchored group (FCSEMS + anchoring DPS) compared with a non-anchored group (FCSEMS alone): 1/16 (6.3%) vs 7/17 (41.2%) respectively, $P = 0.024$. However, in the study by Park *et al*^[10], their sample size was underpowered to identify any significant clinical difference between the two groups and the study was terminated before the planned sample size was reached.

Recently, Katsinelos *et al*^[11] investigated the efficacy of using a 10-Fr DPS to prevent migration in 10 patients with malignant biliary strictures and one patient with a suprapapillary benign biliary stenosis. These patients were prospectively enrolled.

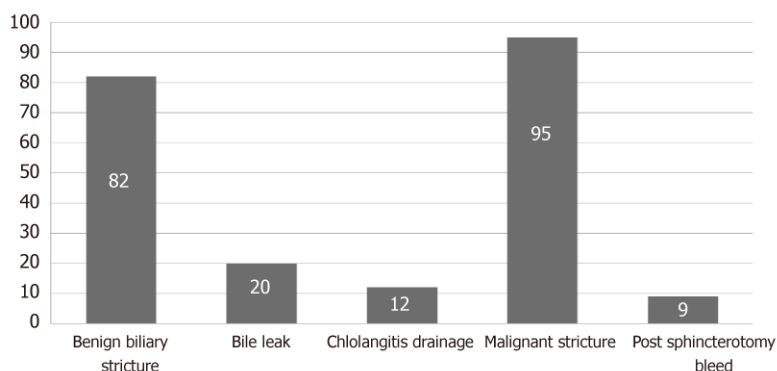


Figure 1 Indication for fully covered self-expandable metal stent with or without double-pigtail plastic stent placement.

The median follow-up period was eight months, and no migration of FCSEMS was reported. Even though it was the first study to assess the use of anchoring a 10-Fr DPS inside an FCSEMS as anti-migration technique, it was limited by small sample size and lack of randomization.

Our study contains a much larger sample size than the studies described above. Also, we included patients with a variety of indications for FCSEMS placement, such as benign and malignant biliary stricture, post sphincterotomy bleed, cholangitis drainage, and bile leak. Our study was different from the above studies because 90% of DPS were 7-Fr and 10% were 10-Fr.

The complication rate from stent migration was very low in our study. Five patients developed obstructive jaundice due to stent migration, and only one patient developed stent-induced cholecystitis secondary to the occlusion of the cystic orifice by a proximally migrated stent in a patient with pancreatic cancer. Acute cholecystitis after placement of a biliary metallic stent has been reported in up to 13% and is likely associated with tumor involvement at the orifice of the cystic duct^[12-14].

This study was limited by being retrospective and not being randomized. However, this is the first study to investigate the efficacy of a 7-Fr DPS inside an FCSEMS as an anti-migration technique and the first study to assess the migration rate of FCSEMS with or without anchoring DPS among those with non-stricture etiologies such post-sphincterotomy bleeding and bile leak.

In conclusion, our findings suggest that anchoring of FCSEMS with a 7-Fr or 10-Fr DPS does not decrease the risk of stent migration. Only benign biliary stricture and previous Sphincterotomy were to have a significant association with stent migrations ($P = 0.01$). We did not find evidence to support the routine placement of anchoring DPS. However, prospective randomized controlled studies are needed to evaluate the efficacy of an anchoring DPS within an FCSEMS as an anti-migration technique.

Table 2 Comparison between patients who had migration of fully covered self-expanding metal stent placement (FCSEMS) and patient who had no migration of FCSEMS

Characteristic	Determinant	Migration (n = 18)	No migration (n = 185)	P-value
Gender	Female	5 (27.8%)	83 (44.9%)	0.1626
	Male	13 (72.2%)	102 (55.1%)	-
Age	mean ± SD (range)	59.83 (12.38) - (34.00, 91.00)	63.28 (15.23) - (23.00, 91.00)	0.3539
Race	Black	2 (11.1%)	7 (3.8%)	0.1494
	White	16 (88.9%)	178 (96.2%)	-
Post sphincterotomy bleed	No	17 (94.4%)	177 (95.7%)	0.8086
	Yes	1 (5.6%)	8 (4.3%)	-
Bile leak	No	18 (100.0%)	165 (89.2%)	0.1418
	Yes	0 (0.0%)	20 (10.8%)	-
Benign biliary stricture	No	6 (33.3%)	115 (62.2%)	0.0173
	Yes	12 (66.7%)	70 (37.8%)	-
Cholangitis drainage	No	18 (100.0%)	173 (93.5%)	0.2653
	Yes	0 (0.0%)	12 (6.5%)	-
Malignant stricture	No	13 (72.2%)	95 (51.4%)	0.0902
	Yes	5 (27.8%)	90 (48.6%)	-
Brand of FCSEMS	Viabil fully covered	8 (44.4%)	82 (44.3%)	0.2294
	Viabil fully covered with proximal fenestration	3 (16.7%)	60 (32.4%)	-
	WallFlex	7 (38.9%)	43 (23.2%)	-
Length of FCSEMS (cm)	4	2 (11.1%)	28 (15.1%)	0.9376
	6	9 (50.0%)	97 (52.4%)	-
	8	5 (27.8%)	42 (22.7%)	-
	10	2 (11.1%)	18 (9.7%)	-
Anchored FCSEMSs with DPS	No	14 (77.8%)	124 (67.0%)	0.3507
	Yes	4 (22.2%)	61 (33.0%)	-
Length of stricture (mm)	mean ± SD (range)	14.67 (10.72) - (0.00, 40.00)	19.65 (19.32) - (0.00, 90.00)	0.0958
CBD diameter (mm)	mean ± SD (range)	11.61 (4.50) - (5.00,22.00)	11.15 (4.70) - (3.00,35.00)	0.6878
History of cholecystectomy	No	5 (27.8%)	87 (47.0%)	0.1173
	Yes	13 (72.2%)	98 (53.0%)	-
Previous sphincterotomy	No	6 (33.3%)	114 (61.6%)	0.0198
	Yes	12 (66.7%)	71 (38.4%)	-
Sphincterotomy at time of stent deployment	No	9 (50.0%)	73 (39.5%)	0.3843
	Yes	9 (50.0%)	112 (60.5%)	-
History of stent migration	No	17 (94.4%)	179 (96.8%)	0.6078
	Yes	1 (5.6%)	6 (3.2%)	-
Choledocholithiasis at time of stent placement	No	16 (88.9%)	172 (93.0%)	0.5272
	Yes	2 (11.1%)	13 (7.0%)	-

FCSEMS: Fully covered self-expanding metal stent; DPS: Double-pigtail plastic stent.

ARTICLE HIGHLIGHTS

Research background

Fully covered self-expandable metal stents (FCSEMSs) have been widely used as an effective biliary endoprosthesis in the setting of pancreaticobiliary conditions such as benign and malignant strictures, post-sphincterotomy bleeding, and occasionally bile leaks. The primary advantages of covered stents are a lower rate of tumor ingrowth, longer patency, and their potential removability compared to uncovered stents. However, one concern about FCSEMSs is a higher migration rate than uncovered stents. In this study, we conducted a retrospective analysis to evaluate the efficacy of 7-French (Fr) and 10-Fr double-pigtail plastic stent (DPS) within the FCSEMS as an anti-migration technique. We compared the rate of stent migration between patients who received FCSEMS alone and those who received both an FCSEMS and anchoring DPS in a large patient population with both benign and malignant strictures as well as non-stricture etiologies. We did not find evidence to support the routine placement of anchoring DPS.

We found that anchoring of FCSEMS with a 7-Fr or 10-Fr DPS does not decrease the risk of stent migration.

Research motivation

FCSEMSs have been commonly used as an effective biliary endoprosthesis in the setting of pancreaticobiliary conditions such as benign and malignant strictures. To minimize the risk of migration, FCSEMSs have been designed with different anti-migration mechanical properties. The use of DPS is still unclear as an anti-migration method. Prospective randomized controlled studies are needed to evaluate the efficacy of an anchoring DPS within an FCSEMS as an anti-migration technique.

Research objectives

The main objective of the study was to assess to the rate of stent migration between patients who received FCSEMS alone and those who received both an FCSEMS and anchoring DPS in both benign and malignant strictures as well as non-stricture etiologies. To our knowledge, there are only two small retrospective studies that have evaluated the efficacy of anchoring DPS to prevent migration of FCSEMS. So, more randomized controlled trials with a larger number of patients are needed.

Research methods

A retrospective analysis of endoscopy reporting system and medical records of patients who underwent ERCP with FCSEMS placement was conducted. The review and analysis were conducted through our endoscopy reporting system (ProVation® MD) and medical records. Patients included in the study had FCSEMS insertion for the treatment of malignant biliary stricture, benign biliary stricture, and non-stricture etiology such as post-sphincterotomy bleeding and bile leak. Data included stent type [Wallflex™ (Boston Scientific) vs Viabil® (Gore Medical)], the diameter of double-pigtail PS (7-Fr vs 10-Fr), and indications for FCSEMS placement. We defined FCSEMS migration endoscopically if the stent was no longer visible through the major papilla. It either migrates proximally (into the bile duct) or distally (out of the bile of duct).

Research results

There was no significant association between any of the other tested variables including anchoring the FCSEMSs with DPS and the risk of stent migration. The migration rate in patients with anchored FCSEMSs with DPS was 6%, and those without anchoring DPS was 10% ($P = 0.35$). Overall, migration was reported in 18 patients with FCSEMS placement out of 203 patients with an overall migration rate of 9.7%. The distribution of patients that had a benign biliary stricture and previous sphincterotomy were significantly different between patients with stent migration and patients with no stent migration.

Research conclusions

In our study, the risk of migration of biliary FCSEMS was 9.7%. Anchoring an FCSEMS with a 7-Fr or 10-Fr DPS does not decrease the risk of stent migration. Routine placement of anchoring stents is unnecessary. We believe that further randomized controlled trials with a larger number of patients might be helpful to ascertain if anchoring an FCSEMS with DPS is useful as an anti-migration technique.

Research perspectives

Anchoring of FCSEMS with a 7-Fr or 10-Fr DPS does not decrease the risk of stent migration. Only benign biliary stricture and previous Sphincterotomy were to have a significant association with stent migrations. Needs more prospective large studies. More randomized controlled trials with a larger number of patients are needed.

REFERENCES

- 1 **Dumoncau JM**, Tringali A, Blero D, Devière J, Laugiers R, Heresbach D, Costamagna G; European Society of Gastrointestinal Endoscopy. Biliary stenting: indications, choice of stents and results: European Society of Gastrointestinal Endoscopy (ESGE) clinical guideline. *Endoscopy* 2012; **44**: 277-298 [PMID: 22297801 DOI: 10.1055/s-0031-1291633]
- 2 **Isayama H**, Komatsu Y, Tsujino T, Sasahira N, Hirano K, Toda N, Nakai Y, Yamamoto N, Tada M, Yoshida H, Shiratori Y, Kawabe T, Omata M. A prospective randomised study of "covered" versus "uncovered" diamond stents for the management of distal malignant biliary obstruction. *Gut* 2004; **53**: 729-734 [PMID: 15082593 DOI: 10.1136/gut.2003.018945]
- 3 **Lee JH**, Krishna SG, Singh A, Ladha HS, Slack RS, Ramireddy S, Raju GS, Davila M, Ross WA. Comparison of the utility of covered metal stents versus uncovered metal stents in the management of malignant biliary strictures in 749 patients. *Gastrointest Endosc* 2013; **78**: 312-324 [PMID: 23591331 DOI: 10.1016/j.gie.2013.02.032]
- 4 **Kitano M**, Yamashita Y, Tanaka K, Konishi H, Yazumi S, Nakai Y, Nishiyama O, Uehara H, Mitoro A, Sanuki T, Takaoka M, Koshitani T, Arisaka Y, Shiba M, Hoki N, Sato H, Sasaki Y, Sato M, Hasegawa K, Kawabata H, Okabe Y, Mukai H. Covered self-expandable metal stents with an anti-migration system improve patency duration without increased complications compared with uncovered stents for distal biliary obstruction caused by pancreatic carcinoma: a randomized multicenter trial. *Am J Gastroenterol* 2013; **108**: 1713-1722 [PMID: 24042190 DOI: 10.1038/ajg.2013.305]
- 5 **Saleem A**, Leggett CL, Murad MH, Baron TH. Meta-analysis of randomized trials comparing the patency

- of covered and uncovered self-expandable metal stents for palliation of distal malignant bile duct obstruction. *Gastrointest Endosc* 2011; **74**: 321-327.e1-3 [PMID: 21683354 DOI: 10.1016/j.gie.2011.03.1249]
- 6 **Isayama H**, Nakai Y, Toyokawa Y, Togawa O, Gon C, Ito Y, Yashima Y, Yagioka H, Kogure H, Sasaki T, Arizumi T, Matsubara S, Yamamoto N, Sasahira N, Hirano K, Tsujino T, Toda N, Tada M, Kawabe T, Omata M. Measurement of radial and axial forces of biliary self-expandable metallic stents. *Gastrointest Endosc* 2009; **70**: 37-44 [PMID: 19249766 DOI: 10.1016/j.gie.2008.09.032]
 - 7 **Park DH**, Lee SS, Lee TH, Ryu CH, Kim HJ, Seo DW, Park SH, Lee SK, Kim MH, Kim SJ. Anchoring flap versus flared end, fully covered self-expandable metal stents to prevent migration in patients with benign biliary strictures: a multicenter, prospective, comparative pilot study (with videos). *Gastrointest Endosc* 2011; **73**: 64-70 [PMID: 21184871 DOI: 10.1016/j.gie.2010.09.039]
 - 8 **Isayama H**, Kawakubo K, Nakai Y, Inoue K, Gon C, Matsubara S, Kogure H, Ito Y, Tsujino T, Mizuno S, Hamada T, Uchino R, Miyabayashi K, Yamamoto K, Sasaki T, Yamamoto N, Hirano K, Sasahira N, Tada M, Koike K. A novel, fully covered laser-cut nitinol stent with antimigration properties for nonresectable distal malignant biliary obstruction: a multicenter feasibility study. *Gut Liver* 2013; **7**: 725-730 [PMID: 24312715 DOI: 10.5009/gnl.2013.7.6.725]
 - 9 **Moon SH**, Kim MH, Park DH, Song TJ, Eum J, Lee SS, Seo DW, Lee SK. Modified fully covered self-expandable metal stents with antimigration features for benign pancreatic-duct strictures in advanced chronic pancreatitis, with a focus on the safety profile and reducing migration. *Gastrointest Endosc* 2010; **72**: 86-91 [PMID: 20493483 DOI: 10.1016/j.gie.2010.01.063]
 - 10 **Park JK**, Moon JH, Choi HJ, Min SK, Lee TH, Cheon GJ, Cheon YK, Cho YD, Park SH, Kim SJ. Anchoring of a fully covered self-expandable metal stent with a 5F double-pigtail plastic stent to prevent migration in the management of benign biliary strictures. *Am J Gastroenterol* 2011; **106**: 1761-1765 [PMID: 21788992 DOI: 10.1038/ajg.2011.212]
 - 11 **Katsinelos P**, Lazaraki G, Gkagkalis S, Chatzimavroudis G, Anastasiadou K, Georgakis N, Giouleme O, Zavos C, Kountouras J. A fully covered self-expandable metal stent anchored by a 10-Fr double pigtail plastic stent: an effective anti-migration technique. *Ann Gastroenterol* 2017; **30**: 114-117 [PMID: 28042247 DOI: 10.20524/aog.2016.0089]
 - 12 **Kahaleh M**, Tokar J, Conaway MR, Brock A, Le T, Adams RB, Yeaton P. Efficacy and complications of covered Wallstents in malignant distal biliary obstruction. *Gastrointest Endosc* 2005; **61**: 528-533 [PMID: 15812404 DOI: 10.1016/j.gie.2011.01.043]
 - 13 **Isayama H**, Kawabe T, Nakai Y, Tsujino T, Sasahira N, Yamamoto N, Arizumi T, Togawa O, Matsubara S, Ito Y, Sasaki T, Hirano K, Toda N, Komatsu Y, Tada M, Yoshida H, Omata M. Cholecystitis after metallic stent placement in patients with malignant distal biliary obstruction. *Clin Gastroenterol Hepatol* 2006; **4**: 1148-1153 [PMID: 16904950 DOI: 10.1016/j.cgh.2006.06.004]
 - 14 **Suk KT**, Kim HS, Kim JW, Baik SK, Kwon SO, Kim HG, Lee DH, Yoo BM, Kim JH, Moon YS, Lee DK. Risk factors for cholecystitis after metal stent placement in malignant biliary obstruction. *Gastrointest Endosc* 2006; **64**: 522-529 [PMID: 16996343 DOI: 10.1016/j.gie.2006.06.022]



Published By Baishideng Publishing Group Inc
7041 Koll Center Parkway, Suite 160, Pleasanton, CA 94566, USA
Telephone: +1-925-2238242
Fax: +1-925-2238243
E-mail: bpgoffice@wjgnet.com
Help Desk: <https://www.f6publishing.com/helpdesk>
<https://www.wjgnet.com>

