

**CASE REPORT***Volume 9 Issue 1****Transdiaphragmatic Intercostal Hernia Repair in a Patient with Previous Thoracic Surgery*****Lilyan T. Starkey, BS<sup>1</sup>, Ruth P. Gerola, MD<sup>1</sup>,  
David A. Denning, MD<sup>1</sup>****ABSTRACT**

A transdiaphragmatic intercostal hernia (TDIH) describes the herniation of abdominal contents through diaphragm and chest wall defects. It has been documented following traumatic injuries as well as after episodes of increased thoracoabdominal pressure. However, those resulting from iatrogenic cause remain uncommon and are less often recorded. We report an iatrogenic TDIH in a patient presenting 39 days after a complicated thoracic procedure, highlighting the surgical technique used for successful hernia reduction, diaphragmatic closure, and rib re-approximation. The case reinforces the possibility of a TDIH occurring as a post-surgical complication. Surgeons should anticipate the potential development of TDIH, particularly after thoracic procedures in patients with significant pre-existing conditions, such as chronic obstructive pulmonary disease (COPD) and cirrhosis. Such clinical awareness should be coupled with apt corrective surgical strategies thereby providing greater opportunity for successful patient recovery.

*Author affiliations are listed at the end of this article.*

***Corresponding Author:***

Lilyan T. Starkey  
Marshall University  
Joan C. Edwards  
School of Medicine  
[wright361@marshall.edu](mailto:wright361@marshall.edu)

**KEYWORDS**

Hernia, transdiaphragmatic, intercostal, iatrogenic

**INTRODUCTION**

The intercostal herniation of abdominal viscera through a diaphragmatic defect is uncommon. In 1911, Gerster detailed the phenomenon in patients who suffered traumatic injuries, referencing it as an "intercostal diaphragmatic hernia."<sup>1</sup> This form of hernia was again reported in 1979 by Croce and Mehta who devised the term "intercostal pleuroperitoneal hernia."<sup>2</sup> When Cole et al. presented a similar hernia in 1986, it was denominated a "transdiaphragmatic intercostal hernia (TDIH)."<sup>3</sup>

Even with longstanding documentation of TDIH, existing literature consists of only case reports and limited case series which utilize heterogeneous nomenclature, describe diverse etiologies, and employ different corrective surgical techniques. Chronicled pathological mechanisms include occurrences after blunt and penetrating trauma, episodes of increased intraabdominal pressure,

and, extremely rarely, iatrogenic injury.<sup>4-5</sup> In this report, a unique iatrogenic TDIH is described in a patient who had recently undergone an attempted thoracic procedure. The case adds an incidence of the uncommon occurrence to the scientific literature and underscores the role of comorbidities, such as chronic obstructive pulmonary disease and cirrhosis, in iatrogenic TDIH development.

**CASE PRESENTATION**

This is a 59-year-old female patient with cirrhosis, chronic obstructive pulmonary disease (COPD), and recurrent episodes of pneumonia with symptomatic TDIH. She initially presented at an outlying hospital with a cough and dyspnea. A CT scan demonstrated pneumonia, a left lower lung abscess, and ascites. She received antibiotic therapy, but symptoms persisted. On hospital day six, a repeat CT chest revealed left pneumothorax with entrapped lung.



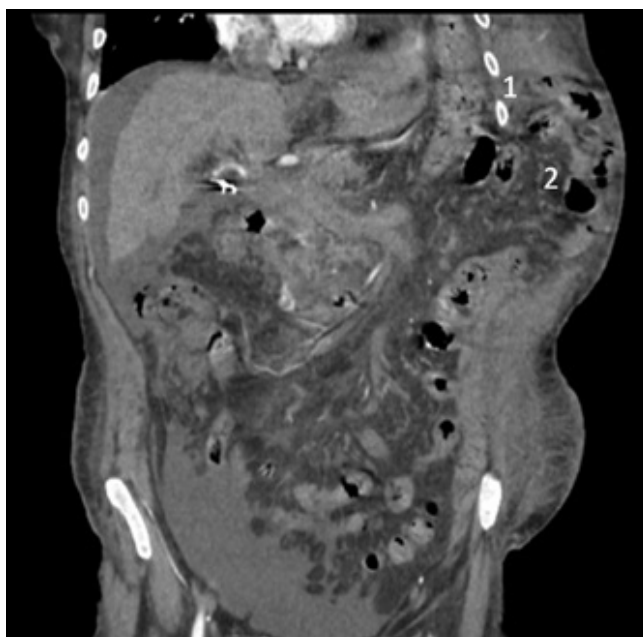
Video-assisted thoracic surgical decortication was attempted. When entering the intercostal space, the port was misplaced in the abdominal cavity, causing a splenic injury. The decortication was aborted, and a splenectomy was performed. The peritoneum and fascia were approximated with 2.0 Vicryl. The ribs were approximated with #1 Vicryl in a figure 8 pattern. The patient was then discharged with long-term IV antibiotics.

The patient presented to our facility on postoperative day 39 complaining of incision ulceration, abdominal pain, and dyspnea. Examination revealed an incisional hernia. A CT scan demonstrated left 8th and 9th rib fractures and a hernia defect along the periphery of the left diaphragm and adjacent left lateral abdominal wall as seen in Figures 1 and 2. The hernia contained transverse and descending colon, stomach, and small bowel, concerning for left transdiaphragmatic intercostal hernia from prior surgery.

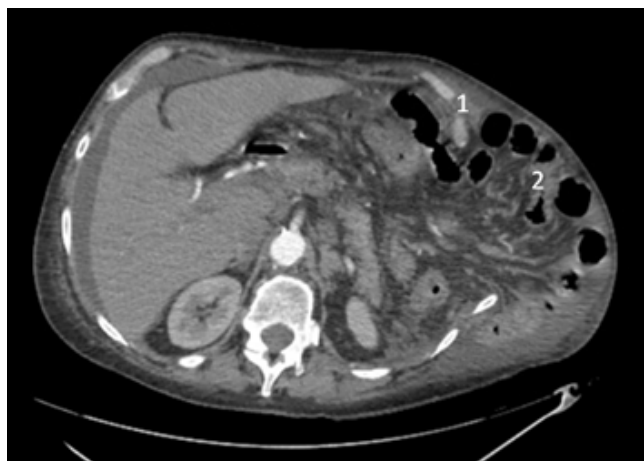
The patient was brought to the operating room. A prior left thoracoabdominal incision was opened into the chest and abdomen. The omentum and intestines were adherent to the diaphragm and the left lung. Adhesiolysis was performed, and the hernia was reduced. Similarly, the ribs were mobilized so they could be reapproximated. The diaphragm was closed with the Smead-Jones technique using #2 Vicryl. A 32 French-angled left chest tube was inserted. The ribs were approximated using figure 8-patterned 2-0 Vicryl. Two Jackson Pratt drains were placed in the subcutaneous tissue. The skin was closed with vertical mattress sutures of 4-0 nylon and skin staples. The post-surgical course was uneventful, and the patient was discharged home.

## DISCUSSION

Development of a transdiaphragmatic intercostal hernia (TDIH) requires destabilization of both the



**FIGURE 1.** Coronal view of the CT scan of the abdomen with incarcerated intestines through the left-sided transdiaphragmatic hernia (1- left rib; 2-intestines).



**FIGURE 2.** Axial view of the CT scan of the abdomen demonstrating displacement of the intestines through the hernia (1- left rib; 2-intestines).



diaphragm and thoracic wall. In the cases reviewed by Sharma et al., situations meeting these anatomic prerequisites include thoracoabdominal trauma and episodes of increased abdominal/thoracic cavity pressure gradient (coughing, straining, and vomiting).<sup>4</sup> Iatrogenic influence on TDIH development is described by Rompen et al. in the report of a patient presenting with TDIH 5 years after undergoing nephrectomy with the intra-operative opening of the hemidiaphragm.<sup>5</sup> Our patient also underwent diaphragmatic opening thereby disrupting the diaphragm's inherent musculature and creating an opportunity for future injury and resultant TDIH.

Another similarity between our patient and the one described by Rompen et al. is the diagnosis of COPD.<sup>5</sup> The comorbidity of COPD is frequently observed in cases of TDIH regardless of whether induced by an iatrogenic event, thoracoabdominal strain, or trauma.<sup>3, 5-9</sup> Authors have postulated that severe coughing in these patients leads to more frequent periods of increased thoracoabdominal pressure gradient and, thus, more opportunities for upwards displacement of abdominal viscera.<sup>6</sup> Furthermore, COPD patients are frequently prescribed steroid therapy for disease exacerbations. Authors have raised the question of whether corticosteroids could disrupt healing in COPD patients' vulnerable diaphragmatic and intercostal musculature, therefore making such patients more susceptible to significant diaphragm injury and consequential TDIH.<sup>6</sup> As our patient had a history of both chronic cough and steroid therapy, these COPD-related factors likely contributed to her development of TDIH.

While not largely described in documented cases of TDIH, liver cirrhosis with resultant ascites is known to raise intra-abdominal pressure and increase the risk for abdominal hernias.<sup>10</sup> This ascites-induced increased intra-abdominal pressure could logically enhance the probability of TDIH as well. Our patient had a known cirrhosis diagnosis. Persistent ascites plausibly furthered her risk for TDIH by further widening the pressure gradient between the abdomen and her compromised thoracic cavity, adding even more stress to the injured diaphragm.

Diagnosis of TDIH is based on physical findings of a palpable mass in the chest wall which increases in size on inspiration and decreases in size on

expiration.<sup>4</sup> The auscultation of bowel sounds within the mass is also suggestive of TDIH.<sup>6</sup> Radiographic imaging can confirm the diagnosis. To avoid incarceration of the hernia contents, TDIH should be promptly addressed.<sup>5</sup> Surgery is the definitive treatment. In most reported cases, a correction has been accomplished by entering the TDIH via either a thoracic or thoracoabdominal incision.<sup>4</sup> Laparoscopic correction has also been successfully utilized.<sup>9,11</sup> The main surgical objective is to adequately visualize the defect so that re-approximation with tension-free closure may be obtained. Some authors report difficulty accomplishing tension-free closure and employ mesh for the diaphragm and inner rib surface.<sup>4</sup> Urgent surgery via open thoracoabdominal approach was performed for our patient, and tension-free closure was achieved without mesh. While a laparoscopic approach would have likely resulted in less intraoperative blood loss, our open technique succeeded in timely defect visualization of the large TDIH and allowed for vast adhesiolysis and tissue mobilization, thereby maximizing the opportunity for tension-free closure.

## CONCLUSION

Transdiaphragmatic intercostal hernias remain rare. Because of the utilization of different nomenclature in existing case reports and the application of various corrective surgical strategies, research and cohesive education on the diagnosis are complicated. Nevertheless, a methodical physical exam combined with appropriate radiological imaging can effectively identify TDIH. Suspicion should be maintained for patients with known trauma, strain, or surgery involving diaphragmatic disruption. Surgeons should anticipate the possible development of TDIH, especially after thoracic procedures in patients with COPD and/or cirrhosis. They should also have knowledge of corrective surgical technique strategies which could provide the patient with successful treatment.

## AUTHOR AFFILIATIONS

1. Marshall University Joan C. Edwards School of Medicine, Huntington, West Virginia



## REFERENCES

1. Gerster JC. Intercostal Diaphragmatic Hernia: With Report of a Case. *Ann Surg.* 1911;54(4):538-548.
2. Croce EJ, Mehta VA. Intercostal pleuroperitoneal hernia. *J Thorac Cardiovasc Surg.* 1979;77(6): 856–857.
3. Cole FH Jr, Miller MP, Jones CV. Transdiaphragmatic intercostal hernia. *Ann Thorac Surg.* 1986;41(5):565-566.
4. Sharma OP, Duffy B. Transdiaphragmatic intercostal hernia: review of the world literature and presentation of a case. *J Trauma.* 2001;50(6):1140-1143.
5. Rompen JC, Zeebregts CJ, Prevo RL, Klaase JM. Incarcerated transdiaphragmatic intercostal hernia preceded by Chilaiditi's syndrome. *Hernia.* 2005;9(2):198-200.
6. Chaar CI, Attanasio P, Detterbeck F. Disruption of the costal margin with transdiaphragmatic abdominal herniation induced by coughing. *Am Surg.* 2008;74(4):350-353.
7. Chapman AA, Duff SB. A case of spontaneous transdiaphragmatic intercostal hernia with contralateral injury, and review of the literature. *Case Rep Surg.* 2017;2017:7416092.
8. Macedo AC, Kay FU, Terra RM, Campos JR, Aranha AG, Funari MB. Transdiaphragmatic intercostal hernia: imaging aspects in three cases. *J Bras Pneumol.* 2013;39(4):513-517.
9. Smith-Singares E. Thoracoscopic management of a traumatic subacute transdiaphragmatic intercostal hernia. Second case reported. *Trauma Case Rep.* 2020;28:100314.
10. Salamone G, Licari L, Guercio G, et al. The abdominal wall hernia in cirrhotic patients: a historical challenge. *World J Emerg Surg.* 2018;13:35.
11. Siow SL, Wong CM, Hardin M, Sohail M. Successful laparoscopic management of combined traumatic diaphragmatic rupture and abdominal wall hernia: a case report. *J Med Case Rep.* 2016;10:11.

